

## Role of Trabecular Metal Augments in Revision Total Hip Arthroplasty with Acetabular Bone Defects

Emad Sanad \*, Samir M Monib, Mohamed A. Abd Elbaky

Department of Orthopedic Surgery Faculty of Medicine, Benha University, Egypt

Corresponding author\*: Emad Sanad, Phone Number: 01011891025, E-mail: [dr\\_emadsanad85@fmed.bu.edu.eg](mailto:dr_emadsanad85@fmed.bu.edu.eg)

### Abstract

**Background:** Annually, a growing number of total hip arthroplasties (THA) are being conducted, and a comparable upward trend has been noted in revision hip procedures.

**Objective:** The objective of this research endeavour is to assess the initial functional and radiological results in patients who are undergoing revision THA and have acetabular defects; trabecular metal augments (TMA) are utilised for acetabular reconstruction.

**Patients and Methods:** A prospective cohort study was conducted on 40 patients undergoing rTHA with loose acetabular component with acetabular defects. The study was done in the period between April 2021 and December 2022 in Benha University Hospital, including forty patients undergoing revision total hip arthroplasty with acetabular defects that necessitate reconstruction. All the patients were followed up for one year. All patients were evaluated with anteroposterior and cross table lateral plain X-ray, immediately postoperatively then at two, six, twelve weeks, six months then annually. Functional outcomes were measured with Oxford Hip Score (OHS).

**Results:** There was no significant difference between Paprosky II and Paprosky III as regard OHS improvement. 2(5%) of patients had fair OHS grade, 16(40%) had good OHS grade, 22(55%) had excellent OHS grade.

**Conclusions:** The promising early results of using THA for acetabular reconstruction convinced more surgeons to start using this system in revision surgeries.

**Keywords:** Acetabular bone defects, Revision total hip replacement, Hip arthroplasty, Bone reconstruction.

### INTRODUCTION

Similar trends have been observed in revision hip procedures and the annual increase in the number of total hip arthroplasties (THAs) performed. In revision total hip arthroplasty and specific primary total hip arthroplasty, acetabular bone stock deficiency is one of the most significant obstacle factors. The objectives of a successful revision surgery are the following: achieving press-fit of the implant, bridging bony defects, and restoring the hip's centre of rotation [1].

Regarding revision total hip arthroplasty, the management of acetabular bone defects is difficult. Porous-coated hemispheric cups have the capability to effectively reconstruct small, contained defects, whether additional allografts are utilised or not. In the presence of sizable uncontained defects, even with the addition of screws, a cementless cup will fail to interlock adequately with the host bone to offer primary stability. Surgical options consist of bilobed oblong cups, reconstruction cages, extra-large hemispheric cups, high hip centre placement, cement impaction grafting, and structural allografts [2,3].

To accomplish these objectives, various strategies have been implemented. Alternative approaches encompass the utilisation of cup-cage configurations, elliptical shells, rings or cages composed of cemented shells, and shells featuring a high centre of rotation. But osseous fixation can be impeded and early failure can result from inadequate primary stability and host-bone contact of less than 50% [4]. Failure by breakage or loosening, as in the case of cages and reinforcement rings, and graft resorption and late failure, as in the case of allograft bone utilised with earlier acetabular component designs, are disadvantages of their use [5].

Custom triflange acetabular components (CTACs; Zimmer Biomet, Warsaw, Indiana) present an alternative option, particularly in cases where chronic pelvic discontinuity is present, in contrast to the unsatisfactory midterm and long-term outcomes observed with antiprotrusion devices and cages, as well as cemented acetabular components. Nonetheless, this construct is costly, its fabrication takes about six weeks, and iatrogenic bone loss during removal of the existing component often prevents it from matching the preoperatively mapped defect [6].

In recent times, augments made of tantalum, a modular porous trabecular metal, have been devised to accomplish biological fixation while also furnishing mechanical support and coverage for an uncemented hemispheric acetabular component. A variety of sizes and shapes are utilised in the production of these cups and augments to accommodate bony defects [7].

The objective of this research endeavour is to assess the initial functional and radiological results in individuals who are undergoing revision total hip arthroplasty (rTHA) and have acetabular defects. Trabecular metal augments (TMA) were utilised to reconstruct the acetabulum.

### PATIENTS AND METHODS

A prospective cohort study was conducted on 40 patients undergoing rTHA with loose acetabular component with acetabular defects. The study was done in Benha University Hospital including forty patients undergoing revision total hip arthroplasty with acetabular defects that necessitate reconstruction. The research was conducted between April 2021 and

December 2022. All the patients were followed up for one year.

**Exclusion criteria** were patient with pelvic discontinuity and patients with neuromuscular disorders.

All patients were subjected to personal history including occupation, age, sex, special habits of medical importance, abductor's function, previous surgical approach, and range of motion.

Nineteen patients have one previous history of total hip replacement and only one patient had two previous total hip replacements. Fourteen patients were done through posterior approach and six patients through lateral approach.

History and medical comorbidities, twelve patients had no previous history of chronic medical condition, seven patients had chronic disease either (DM (Diabetes mellites), HTN (hypertension), Rheumatoid) and only one patient had both DM and HTN.

Local and neurovascular assessment of the affected limb: The Trendelenburg test was used to evaluate the status of the abductor muscle, which resisted side-lying abduction. The leg-length disparity was assessed: preoperative discussion with the patient included trials that would be done to equalize the length of both limbs and at least to decrease the difference. In difficult revision cases, instability had priority over leg length equalization.

The Oxford hip scoring system was used to record the status of the hip before surgery to be able to evaluate postoperative results.

#### ***Radiological evaluation:***

Plain lateral and anteroposterior radiographs of the hip, as well as a CT scan, were utilized to radiologically examine every patient (to classify the acetabular defects).

Laboratory assessment: CBC, Kidney function

Paprosky classification system: Distribution of patients according to Paprosky classification systems was done. Fifteen patients were Paprosky type II, and five patients were type IIIA.

Surgical technique: During every operation, the patient was in a lateral position while lying. All patients received combined spinal (subarachnoid) anesthesia, and epidural anesthesia. IV tranexamic acid (15 mg/kg) was taken routinely in the OR with induction of anesthesia. IV antibiotics: Twelve patients received a double dose (2 gm) of third generation cephalosporin intravenously at the induction of anesthesia. The remaining eight patients followed the protocol for management of infected cases.

#### **Operative steps**

##### ***Through the posterior approach:***

Old incisions were used whenever possible. However, skin incision was modified in many occasions to allow for posterior approach or incorporate draining sinuses. In cases requiring revision, the incision was typically extended distally and proximally in order to

facilitate extensile exposures when necessary and to more easily define tissue planes for scar release. The sciatic nerve was routinely identified and palpated. The scarred external rotators were released and reflected posteriorly with the leg maximally extended and internally rotated.

#### **Closure of the wound**

Reattachment of the posterior soft tissues including short external rotators to the greater trochanter was done. The iliotibial band was then closed after application of suction drain.

Skin closure using skin clips was done.

#### **Postoperative care**

Postoperative antibiotic regimen was given as ceftriaxone 2 gm infusion every 24 hours for 48 hours. In the infected cases, antibiotics were given according to the results of intraoperative samples. Low molecular weight heparin 40 I.U. once daily started 12 hours after the surgery and maintained for one month. Proton pump inhibitors were given till discharge. Hemoglobin concentration was assessed for every case at least 6 hours after the last transfused blood unit. Blood transfusion was given if HB concentration was less than 9 gm/dl. Static quadriceps and hamstring exercises and straight leg raising were performed. The timing of postoperative partial weight bearing was variable according to the structural integrity of the acetabular reconstruction and the implant used. Twelve weeks were added to the patient's full weight-bearing duration following trochanteric osteotomy. At six weeks, the remaining cases commenced full weight bearing.

#### **Radiological evaluation**

All patients were evaluated with anteroposterior and cross table lateral plain X-ray immediately postoperatively then at two, six, twelve weeks, six months then annually.

#### **Functional outcomes were measured with Oxford Hip Score (OHS).**

#### **Ethical Approval:**

**Written informed consent was obtained from the patient or their legal guardians. Approval from the Ethical Committee of Benha University Hospital (approval code: Rc 12-12-2023) was obtained. This work has been carried out in accordance with The Code of Ethics of the World Medical Association (Declaration of Helsinki) for studies involving humans.**

#### **Statistical analysis**

Analysis of statistics was performed using SPSS v25 (IBM Inc., Chicago, IL, USA). Quantitative variables were expressed as mean and standard deviation and were compared for the same group, using a paired Student's t-test and for 2 groups by independent t-test.

Frequency and percentage were used to represent qualitative variables and were compared by chi<sup>2</sup> test. P <0.05 was considered significant.

**CASE**

**History:** Female patient 64 years old, housewife, no past medical history, obese (BMI 32.7 kg/m<sup>2</sup>).

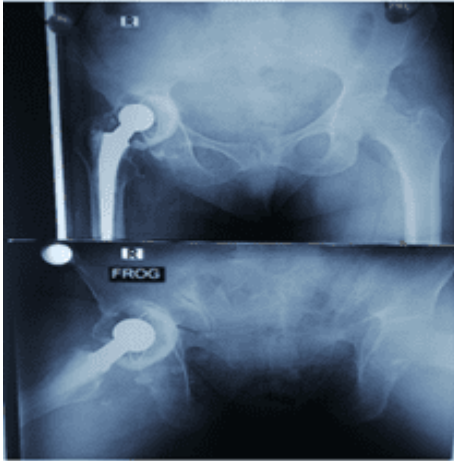
**Diagnosis:** aseptic loosening of the acetabular component.

**Type of defect:** Paprosky: 2B and AAOS: 2A


**Operative details:** revision of acetabular component .

**Clinical evaluation:** OHS preoperatively was 13, postoperatively was 40.

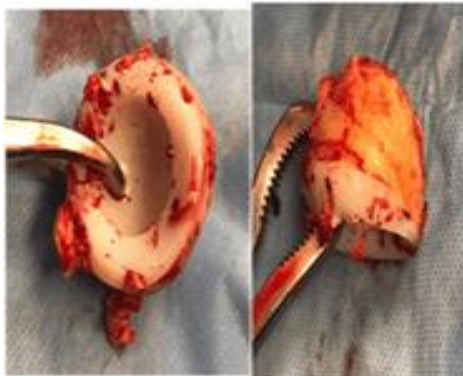
**Complications:** Sciatic nerve affection in the form of foot drop for which NCV was done and showed neurotmesis and till the last follow up still was not recovered (**Figure 1-8**).



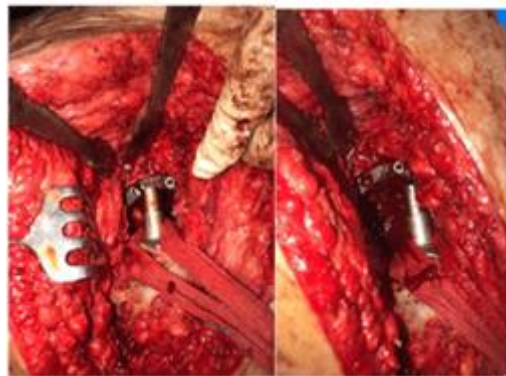**Figure 1: Preoperative X-ray**



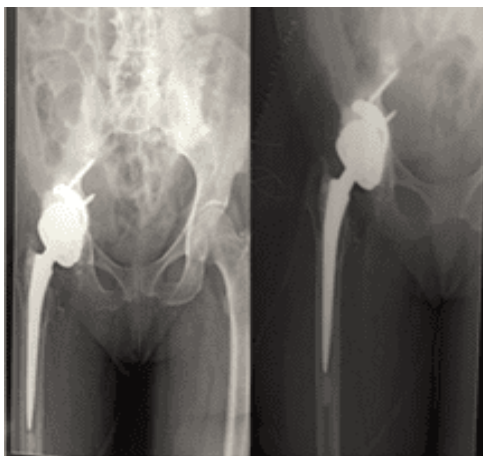
**Figure 2: Preoperative C.T**



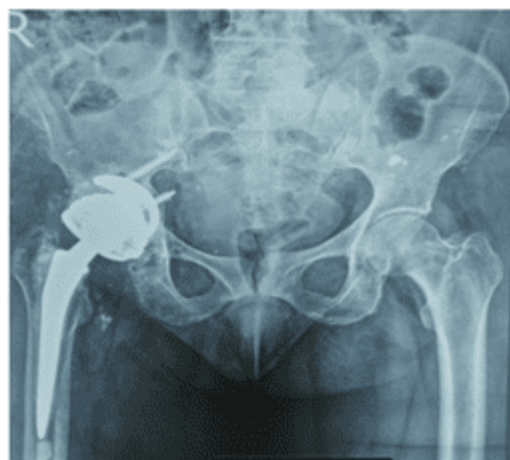**Figure 3: Removed polyethylene cup**



**Figure 4: Intraoperative photo after augment insertion.**



**Figure 5: Postoperative X-ray**



**Figure 6: Follow up X-ray after 3 months**

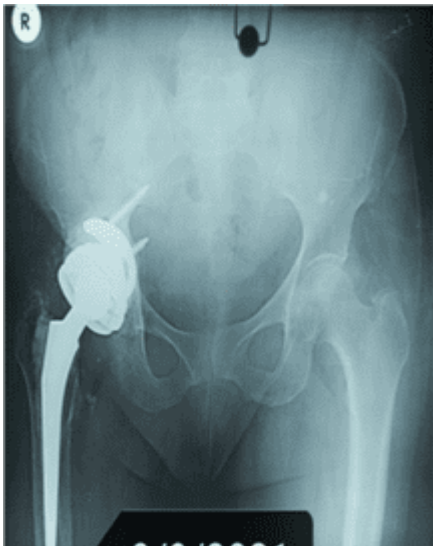

Figure 7: Follow up X-ray after 6 months

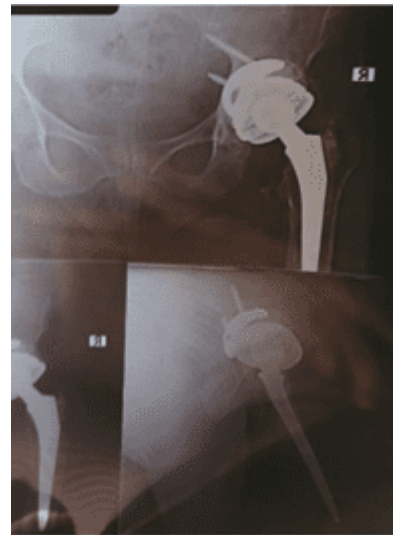

Figure 8: Follow up X-ray after 14 months

**RESULTS**

**Sex distribution:** The study comprised 25 males (37.5 %) and 15 females (62.5 %). The participants' ages varied from 35 to 70, with a mean age of 48 years. Thirty (75 %) of the patients underwent operations on the right side, while the remaining 10 (25 %) underwent operations on the left side. Indications for surgery: 24 patients for septic loosening and 16 patients for aseptic loosening.

OHS was significantly higher postoperatively compared to preoperatively (Table 1).

**Table 1: Comparison of mean preoperative and postoperative OHS**

OHS	Mean ± SD (n=40)		P- value
	Preoperative	Postoperative	
	11.75 ± 3.99	37.8 ± 4.98	0<0.001

Data are presented as mean ± SD, OHS: Oxford Hip Score, SD = standard deviation.

Cementless acetabular components were used in eleven cases in this study. All the cases showed excellent results at the end stage follow up. No radiological failure was found. No revision for infection or any other cause was found.

There was no significant difference between Paprosky II and Paprosky III as regard OHS improvement (Table 2).

**Table 2: Mean improvement in OHS in different groups**

OHS improvement	Mean ± SD (n=40)		P value
Type of defect	Paprosky II	Paprosky III	
	67.66± 8.72	74.24± 11.13	0.061
Presence of infection	Infected	Non-infected	0.714
	67.21± 7.89	68.35± 10.12	
IBG usage	IBG	No IBG	0.967
	67.10± 8.54	67.23± 8.99	

Data are presented as mean ± SD, OHS: Oxford Hip Score, IBG: Iliac bone graft SD = standard deviation

**Grading of OHS at last follow up visit:**

Excellent OHS grade was the most common grade (Table 3).

**Table 3: OHS grading results.**

OHS grade	Number of patients (n=40)	Percentage (%)
Fair	2	5%
Good	16	40%
Excellent	22	55%
Total	40	100%

Data are presented as number (%), OHS: Oxford Hip Score.

**Type of defect**

There was a significant relation between OHS grading and type of defect (Table 4).

**Table 4: OHS grading results according to type of defect.**

Type of the defect	Paprosky II	Paprosky III	P value
Fair	0(0%)	2(20%)	<0.001
Good	22(73.33)	8(80%)	
Excellent	8(26.67%)	0(0%)	
Total	30	10	

Data are presented as number (%), \*: significant P value.

**Cause of loosening**

The cause of loosening differs significantly between the infected and non-infected groups (Table 5).

**Table 5: OHS grading results according to cause of loosening.**

Cause of loosening	Infected	Non-infected	P value (Chi-square test)
Fair	2(8.03%)	0	0.003
Good	14(58.33%)	2(12.55)	
Excellent	8(33.33%)	14(87.5%)	
Total	24	16	

## Radiological results

### Signs of unstable augment

Radiolucent line appeared in one case after 8 months and it was asymptomatic. The extension of that line didn't change over 16 months of postoperative follow up. No revision was done.

**Signs of cup migration:** No migration of any cup was discovered in relation to the interteardrop line. Regarding the abduction angle, there was no statistically significant difference observed between the initial postoperative period and the most recent follow-up radiographs.

### Bone graft

The bone-graft interface was assessed in the following three DeLee and Chandler zones: No graft fracture, no radiolucent lines in the interface, no graft resorption. Graft incorporation was confirmed by cup and augment stability without incidence of migration.

## DISCUSSION

Reconstructing acetabular bone stock defects that occur during hip arthroplasty presents a formidable challenge for the surgeon, particularly when dealing with large defects such as Paprosky types II and III. It is readily apparent from a review of the relevant literature that no single gold standard method exists for reconstructing these flaws. The choice is significantly influenced by the surgeon's personal inclination and level of expertise<sup>[8]</sup>. The long-term complications of the previously standard techniques such as cages, rings and bulk grafts have led the surgeons to look for alternative materials to option for acetabular reconstruction.

In the current study, OHS has improved from 11.75 preoperatively to 37.8 at the latest follow up visit. According to OHS grading, 2(5%) of patients had fair OHS grade, 16(40%) had good OHS grade, 22(55%) had excellent OHS grade. The results were in the same line with **Grappiolo et al.**<sup>[9]</sup> who used trabecular metal augments in 42 patients with type 3A defects for 53.7 months. Prior to and following the procedure, the mean HHS was 40; it rose to 90.5 afterward.

A retrospective review of 37 acetabular revisions in 36 patients, who were treated with a porous tantalum acetabular component and augment, was conducted by **Del Gaizo et al.**<sup>[10]</sup> Type IIIA defects were present in all patients according to the classification system developed by **Paprosky et al.**<sup>[8]</sup> A radiographic examination was conducted in addition to obtaining Harris hip scores prior to surgery and throughout the most recent follow-up period. 26 months was the minimum follow-up period. A revision was necessary for one patient who experienced aseptic loosening of the acetabular reconstruction. Additionally, seven other patients necessitated additional surgical intervention due to periprosthetic femoral fractures (two), acute infections (three), and recurrent dislocations (two). 37.5 % of 37 hips exhibited no or occasional pain at the time of the final follow-up. The postoperative mean

Harris hip score increased from 33.1 preoperatively to 81.5.

Cementless acetabular components were used in eleven cases in this study. All the cases showed excellent results at the end stage follow up. No radiological failure was found. No revision for infection or any other cause was found. However, this short term follows up needs to be extended for longer periods and other cases using the same combination should be followed up to get more consistent results.

The clinical and radiographic outcomes of porous metal augments in cemented and uncemented acetabular revisions, all performed at the same institution, were analysed by **Mahmoud et al.**<sup>[11]</sup>. Between 2006 and 2015, they documented 104 cemented and 43 uncemented acetabular revisions with metal augments. At the mean follow-up of 60.1 months, a total of 5 cups (3.4 %), of which 2 cups (4.6 %) were uncemented and 3 cups (2.8 %) were cemented, exhibited indications of aseptic loosening with the cup and increased migration; four of these cups were subsequently reevaluated (2.7 %). In revision hip arthroplasty, they concluded that porous metal augments exhibit comparable excellent radiographic and clinical midterm outcomes when combined with cemented or uncemented cups.

A comprehensive series of 85 hips was examined in **Lee et al.**<sup>[12]</sup>'s study, which involved acetabular revision with minor column allografts for defects affecting 30–50 percent of the acetabulum and a minimum 5-year follow-up (mean 16 years). Upon 15- and 20-year follow-up, the authors documented graft survivorship of 81 percent and cup survivorship of 67 percent, respectively.

In their study, **Whitehouse et al.**<sup>[13]</sup> assessed 53 acetabular revisions that utilised trabecular metal augments. They reported a 92% survivability rate with a median follow-up period of 9 years. In revision THA, porous metal augments have gained popularity as an alternative reconstruction strategy to achieve biologic fixation and prevent graft resorption over time, despite the favourable survivability of structural allografts.

In 15 hips, **Gill et al.**<sup>[14]</sup> investigated whether the combination of trabecular metal wedges used to fill segmental defects, impaction grafting, and implantation of a cemented socket is an effective method of socket reconstruction. A radiographic examination revealed the formation of radiolucent lines around the cup of two hips. A patient exhibited a radiolucent line (RLL) in zone 2 of the acetabulum. Despite this, the RLL did not progress on the most recent X-rays, and the patient remains asymptomatic at the 60-month follow-up. Another patient presented with an RLL in zone 2, but despite this, the condition had not advanced and the patient remained asymptomatic at the 26-month follow-up. **Grappiolo et al.**<sup>[9]</sup> deemed the prosthetic construct unstable in the presence of component migration or the crossing of a radiolucent line with a minimum width of 1 mm through all three acetabular zones. As per their criteria for describing RLL and unstable construction,

neither complete radiolucent lines nor failures occurred when cementless components were utilised. In four instances, a radiolucent line was observed. Stable radiolucent lines were observed in three patients at some point during the follow-up period. When present, these radiolucencies were consistently measured at each follow-up appointment in all three patients at a level below 1 mm. A radiolucency in zone II, adjacent to the acetabular augment, was observed in the initial patient at the one-year follow-up. This condition persisted without any changes at the final follow-up. On immediate postoperative radiographs, a radiolucent line in zone III was observed in the second patient; this line remained stable at the time of final follow-up. At the 1-year follow-up, the third patient exhibited radiolucency in Zone I, which was in close proximity to an acetabular augment. During the final follow-up after 30 months, this line had been eliminated. At reoperation, it was determined that a progressive radiolucency in Zone III adjacent to the uncemented hemispheric shell was due to the onset of a postoperative pelvic discontinuity situated below the hemispheric cup's equator. During the follow-up of the remaining patients, neither the augment-bone nor cup-bone interfaces exhibited radiolucent lines at any of the observation points. Migration was not observed in any of the acetabular augment-cup constructs throughout the duration of the study.

In the current research, one patient started to have a radiolucent line in zone 1 at one year follow-up. This line was stable and didn't extend in the next follow-up visit. It didn't affect the result of the patient, which was excellent according to OHS grading.

One month after surgery, one patient in the study by **Nehme et al.**, [15] experienced a postoperative dislocation; the condition was effectively managed through closed reduction, and there has been no subsequent occurrence of hip instability. Subjective instability and recurrent subluxation without dislocation were observed in another patient. Both patients who presented with hip instability underwent a solitary acetabular revision, with no corresponding femoral component revision.

The limitations of this study include absence of a control group, the cost of the augment, large diversity of cases and a relatively small patients number, the follow up is relatively short.

Following this group of patients for longer periods and adding more cases to each category will make the results of this research more valuable and allow for reaching definite answers for questions like definite indications of different types of augments and long-term outcome of this technique.

## CONCLUSIONS

The promising early results of using THA for acetabular reconstruction convinced more surgeons to

start using this system in revision surgeries. As a result of their adaptability and capacity to reconstruct various types of defects without causing bone resorption concern, porous metal augments are regarded as an effective treatment for acetabular defects. Augments are stable at short term follow-up in this study. They can be used in different types of defects. Their use is technically easy and there is no fear of resorption.

- **Funding:** Nil.
- **Conflict of Interest:** Nil.

## REFERENCES

1. **Dwivedi C, Gokhale S, Khim H et al. (2017):** Acetabular defect reconstruction with trabecular metal augments: Study with minimum one-year follow-up. *Hip Pelvis*, 29:168-75.
2. **Johanson N, Driftmier K, Cerynik D et al. (2010):** Grading acetabular defects: the need for a universal and valid system. *Journal of Arthroplasty*, 25:425-31.
3. **Griffin A, Perriman D, Bolton C et al. (2014):** An in vivo comparison of the orientation of the transverse acetabular ligament and the acetabulum. *Journal of Arthroplasty*, 29:574-9.
4. **Löchel J, Janz V, Hipfl C et al. (2019):** Reconstruction of acetabular defects with porous tantalum shells and augments in revision total hip arthroplasty at ten-year follow-up. *Bone Joint J.*, 101-B:311-6.
5. **Jenkins D, Odland A, Sierra R et al. (2017):** Minimum five-year outcomes with porous tantalum acetabular cup and augment construct in complex revision total hip arthroplasty. *The Journal of Bone and Joint Surgery American*, 99:49-55.
6. **Eachempati K, Malhotra R, Pichai S et al. (2018):** Results of trabecular metal augments in Paprosky IIIA and IIIB defects: A multicentre study. *The Bone & Joint Journal*, 100:903-8.
7. **Nieminen J, Pakarinen T, Laitinen M (2013):** Orthopaedic reconstruction of complex pelvic bone defects. Evaluation of various treatment methods. *Scandinavian Journal of Surgery*, 102:36-41.
8. **Paprosky W, Burnett R, Martin E (2001):** Current topics in revision total hip replacement: Acetabular deficiency and its management. *Techniques in Orthopaedics*, 16:227-36.
9. **Grappiolo G, Loppini M, Longo U et al. (2015):** Trabecular metal augments for the management of Paprosky type III defects without pelvic discontinuity. *J Arthroplasty*, 30:1024-9.
10. **Del Gaizo D, Kancherla V, Sporer S et al. (2012):** Tantalum augments for Paprosky IIIA defects remain stable at midterm followup. *Clinical Orthopaedics and Related Research*, 470:395-401.
11. **Mahmoud A, Sundberg M, Flivik G (2017):** Comparable results with porous metal augments in combination with either cemented or uncemented cups in revision hip arthroplasty: An analysis of one hundred forty-seven revisions at a mean of five years. *Journal of Arthroplasty*, 32:1612-7.
12. **Lee P, Raz G, Safir O et al. (2010):** Long-term results for minor column allografts in revision hip arthroplasty. *Clinical Orthopaedics and Related Research*, 468:3295-303.
13. **Whitehouse M, Masri B, Duncan C et al. (2015):** Continued good results with modular trabecular metal augments for acetabular defects in hip arthroplasty at 7 to 11 years. *Clinical Orthopaedics and Related Research*, 473:521-7.
14. **Gill K, Wilson M, Whitehouse S et al. (2013):** Results using trabecular metal™ augments in combination with acetabular impaction bone grafting in deficient acetabula. *HIP International*, 23:522-8.
15. **Nehme A, Lewallen D, Hanssen A (2004):** Modular porous metal augments for treatment of severe acetabular bone loss during revision hip arthroplasty. *Clinical Orthopaedics and Related Research*, 9:201-8.