

Importance of Rouviere's Sulcus in Laparoscopic Cholecystectomy

Taha Yassein1, Tarek Mohammed Ibrahim1, Ahmad Said Ali Dawoud1, Yahya Ahmed Fayed1*

¹Department of Hepato-Pancreato-Biliary Surgery, National Liver Institute, Menoufia University, Menoufia, Egypt

*Corresponding author: Ahmad Said Ali Dawoud, Mobile: (+20)1002859910

E-mail: Dawoud409@gmail.com

ABSTRACT

Background: Rouviere's sulcus (RS) is an important anatomical landmark during laparoscopic cholecystectomy. The initiation of a secure dissection is determined by this sulcus serving as the initial reference point.

Objectives: This work aimed to ascertain Rouviere's sulcus' frequency and significance as a marker in laparoscopic cholecystectomy procedures.

Patients and methods: this is a prospective study on 155 cases who underwent laparoscopic cholecystectomy (LC) at the National Liver Institute–Menoufia University & presented with symptoms of gallstone disorder .

Results : study participants are 155 patients, 95(62%) females and 60(36%)males. RS was visible in 127(82%) patients, RS was found in 80(63%) females and in 47(37%)males. Calot dissection was done above in 109 (70%) patients & at level of the RS in 46(30%) patients, biliary injury, blood loss appeared in 2 (1%) & 2 (1%) patients respectively. 4(2%) were converted to open cholecystectomy. Collection was present in 5(3%) patients. Postoperative wound infection occurred in 4(2%) patients and drain was present in 148(95%) patients.

Conclusion: RS is an easily distinguishable anatomical mark that should be well identified for safe Laparoscopic cholecystectomy.

Keywords: Laparoscopic Cholecystectomy, Rouviere's Sulcus, Gallstone disease

conducted between (June 2021 and January 2023).

INTRODUCTION

For gallstone disease, laparoscopic cholecystectomy is the accepted standard technique. When compared to open cholecystectomy, laparoscopic cholecystectomy is linked to a higher risk of biliary, vascular, and visceral complications ⁽¹⁾.

Bile duct damage during laparoscopic cholecystectomy is over 5% of cases ⁽²⁾. Bile duct injuries still occur, and the rates of damage have not decreased despite the advancements in laparoscopic surgery ⁽³⁾.

The surgeon must take every precaution to reduce the danger of bile duct damage because of the seriousness of this complication. During laparoscopic cholecystectomy, precise recognition of the hepatobiliary anatomy is essential ⁽⁴⁾.

The fissure that carries M.H. Rouviere's name was first identified by the French surgeon in 1924. A 2–5 cm sulcus known as Rouviere's sulcus runs anterior to the caudate lobe and to the right of the liver hilum. It includes the branches of the right portal triad. Cholangiographic investigations have shown that the sulcus properly determines the plane of the common bile duct. In 80% of instances, it is identifiable. This sulcus is considered the beginning point of reference for a safe dissection. Throughout surgery, it is important to continually keep this sulcus' plane in mind. This extra-biliary reference point is a fixed feature on the liver surface that is unaffected by disease ⁽⁵⁾.

This study's objective was to ascertain Rouviere's sulcus' frequency and significance as a marker in laparoscopic cholecystectomy procedures.

PATIENTS AND METHODS

This is a prospective study on 155 patients who had symptomatic illness of gallstones & suffered LC in National Liver Institute – Menoufia University

Inclusion criteria: Symptomatic gallstone disease, early acute cholecystitis within 7 days, and candidate for laparoscopic cholecystectomy. Age eligible for study was above 18 years and both sexes were included. Gall bladder polyps: Less than 1 cm.

Exclusion criteria: High risk for bleeding problem, blood coagulation malfunction, suspected cancer, end stage hepatic disorder with portal hypertension and severe coagulopathy, cardiac, end stage liver conditions, ASA V and VI, and general anesthesia.

All patients were subjected to:

History taking, a comprehensive clinical evaluation, general assessment, local abdominal assessment.

Investigations

Complete blood count (CBC), serum electrolytes, serum creatinine, serum urea, fasting plasma sugar, tests for liver function (including AST, ALT, Alkaline phosphatase, GGT, and coagulation profile), blood group, and crossmatch were done.

Imaging Investigations: abdomen and pelvis ultrasound.

Procedure

The operative data, which included the existence or lack of adhesion, Rouviere's sulcus, and the dissection of the Calot's triangle at or slightly above the level of Rouviere's sulcus with the detection of the cystic artery and cystic duct, were recorded following written informed consent for laparoscopic cholecystectomy.

Steps: we used the American technique

For the laparoscopic cholecystectomy, the conventional four ports approach was used. The first port utilized for the camera was 10 mm at the umbilicus.

Right lateral to the falciform ligament, at the epigastrium, was where the second 10 mm port was created. This port was utilized to deliver gall bladders and to hold equipment for dissection. The third port was a 5 mm port created at the midclavicular line, below the right costal margin. For fundal retraction, a fourth, 5 mm port was created beneath the costal margin in the anterior axillary line. Using a 5 mm port, the gall bladder was retrieved from the infundibulum, cephalad for linear retraction, and the calot's triangle was opened for dissection. Behind the infundibulum, Rouviere's sulcus was searched for; its presence or absence will be recorded. After cutting the cystic duct and artery, the dissection of Calot's triangle was performed above the level of Rouviere's sulcus to acquire a critical view of safety, which is crucial for a safe cholecystectomy. Gallbladder extracted from the cystic plate. Following surgery, several problems were noted, such as biliary leakage, obstructive jaundice, indications of clipping, and damage to the biliary tree.

Ethical Considerations: This study was ethically approved by Department of Hepato-Pancreato-Biliary Surgery, National Liver Institute, Menoufia University Egypt, and the Research Ethics Committee of the Faculty of Medicine, Menoufia University. Written informed consent of all the participants was obtained. The study protocol conformed to the Helsinki Declaration, the ethical norm of the World Medical Association for human testing.

Statistical analysis

Key findings were tallied and statistically examined utilizing the Statistical Package for the Social Sciences (SPSS) version 16 software and appropriate statistical techniques. The quantitative findings were displayed as mean ± standard deviation (SD), range, and percentages, whereas categorical data were shown as numbers and percentages.

RESULTS

The mean age of this study was 41.83 ± 11.39 years, representing a range of ages from eighteen to seventy years old. Out of the total patients, sixty patients (38 percent) were men& ninety-five (sixty-two percent were women. The rouviere's sulcus, was found in 80(63%) female patients & in 47 (37%) male patients (Table 1).

Table (1): baseline attributes of research participants

		Study participants (n =155)
Age (year)	Mean ± SD	41.83 ± 11.39
	Range	18 – 70
Gender	Males	60 (38%)
	Females	95 (62%)

The research participants' most prevalent indications were symptomatic gall stones in form of biliary pain in 64 (41%) patients, followed by chronic calcular cholecystitis in 25 (16%) patients, but the least common indications were CBD stones and asymptomatic gall stones in 7 (5%) and 11(7%) patients respectively. Polyp in 6 (4%) and other indication as noncalcular cholecystitis in 4 (3%) patients (Table 2).

Table (2): Preoperative data of the study participants

		Study participants (n =155)
Indications of cholecystectomy	Biliary pain	64 (41%)
	Chronic calcular cholecystitis	25(16%)
	Acute cholecystitis	20 (13%)
	post attack of Biliary pancreatitis	18 (11%)
	Asymptomatic gallstone	7 (5%)
	CBD stones	11 (7%)
	GB Polyp	6 (4%)
	Other indications	4 (3%)

CBD: Common bile duct

127 (82%) patients exhibited evident sulcus, while adhesions were present in 20% (13%) patients. Calot dissection was performed above the level of the Rouvier's sulcus in 46 (30%) patients & at the level of the 109 (70%) patients; biliary injury & blood loss occurred in 2 (1%) & 2 (1%) patients, respectively. An open cholecystectomy was performed in only 4 patients (2%). (Table 3).

Table (3): Intraoperative information from research subjects

		Study participants (n =155)
Adhesions	Present	20 (13%)
	Not present	135 (87%)
Rouviere's Sulcus	Visible	127 (82%)
	Not visible	28 (18%)
	Above	109 (70%)
	At	46 (30%)
Biliary complications	Yes	2 (1%)
	No	153 (99%)
Blood loss	Yes	2 (1%)
	No	153 (99%)
Conversion to open	Yes	4 (2%)
	No	151 (98%)

Out of all the patients, only 4 (2%) had an open cholecystectomy due to a technical issue (1 instance), severe adhesion, inflammatory response, anatomic distortion in (1 instances), and biliary injury in one patient. According to our data, there was a link between the GB stones and the RS in the following instances: 50 (78%) of the patients with biliary pain had the RS. In 20 (80%) of the instances of chronic calcular cholecystitis, and in 17 (85%) of the instances of acute cholecystitis, the RS was present (Figure 1).

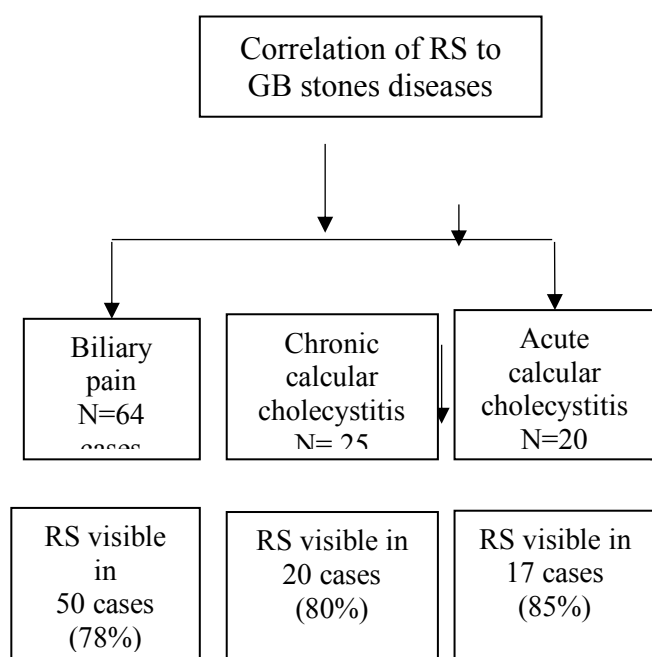


Figure (1): Correlation of RS to GB stones diseases

Regarding postoperative data in the study participants, collection was present in 5 cases, biliary leak in 2 cases. Postoperative wound infection occurred in 4 cases and drain in 148 cases (Table 4).

Table (4): Postoperative information from research subjects

		Study participants (n =155)
Collection	Present	5 (3%)
	Not present	150 (97%)
Biliary leak	Present	2 (1%)
	Not present	153 (99%)
Postoperative wound infection	Yes	4 (2%)
	No	151 (98%)
Drain	Inserted	148 (95%)
	Not	7 (5%)

Patients whose RS was not visible had much longer hospital stays and surgery times than patients whose RS was evident (p <0.001, =0.008, respectively) (Table 5).

Table (5): The length of the research participants' hospitalization and operation

		RS visible (n =127)	RS not visible (n =48)	P-value
Duration of operation including anesthesia (minutes)	Mean ± SD	97.76 ± 22.14	125.75 ± 17.11	<0.001*
	Range	25 – 140	60 - 180	
Length of hospitalization (days)	Mean ± SD	1.28 ± 0.52	1.35 ± 1.15	0.008*
	Range	1 – 3	1 – 4	

IQR : Inter quartile range SD : Standard deviation

DISCUSSION

Given that the CBD is located below the level of the Rouviere's sulcus, and the cystic duct and artery are anterosuperior to it, locating the sulcus in laparoscopic cholecystectomy is advantageous. **Peti and Moser** (6) stated that during laparoscopic cholecystectomies, Rouviere's sulcus may be identified as a crucial anatomical marker to prevent damage to the bile duct. There is very little research on the surgical significance of CBD during laparoscopic cholecystectomy, even though it has the potential to be a crucial anatomical reference point for determining CBD's position (7).

The age distribution of the research participants was 41.83 ± 11.39, with a range of 18 to 70 years. This study included a total of 155 patients, 95 (62%) were females and 60 (38%) were males. 127 cases (82%) had visible RS. In our investigation, the Rouviere's sulcus was discovered in 47 male cases (78% of all male cases) and 80 female patients (89% of all female instances).

Kumar et al. (8) reported that, it is thought that females are more vulnerable because of their sex hormones. Bile becomes supersaturated due to an increase in biliary cholesterol production caused by estrogen.

According to our findings, the most common reason for cholecystectomy among study participants was biliary pain 64 (41%). Chronic calcular cholecystitis affected 25 patients (16%), followed by acute cholecystitis in 20 patients (13%) and biliary pancreatitis in 18 patients (11%). The least common indications were CBD stones and asymptomatic gall stones in 11 (7%) and 7(5%) patients respectively. Polyp in 6(4%) and other indication as noncalcular cholecystitis in 4 (3%) participants.

Regarding our data, the correlation of the RS to the GB stones: The RS was found in 50 (78%) of biliary pain cases, in 20(80%) of chronic calcular cholecustitis cases and in 17(85%) of acute cholecystitis cases.

According to **Jha et al.** ⁽⁷⁾ who studied the Rouviere's sulcus' frequency, shape, and relationship to the common bile duct (CBD). According to their findings, 20 patients (20.41%) had several gallstones, whereas 79 patients (79.59%) had a single gallstone.

Our study showed that, regarding intraoperative data, sulcus was visible in 127 (82%) cases. This is supported by **Thapa et al.** ⁽⁹⁾ who stated that 75% of patients reported having a visible Rouviere's sulcus.

In agreement with a research by **Hugh et al.** ⁽¹⁰⁾ Rouviere's sulcus was found in 319 (79.3%) of the 402 instances of laparoscopic cholecystectomy and missing in 80 (20.7%) of the cases.

According to **Elwan** ⁽¹¹⁾ who investigated the advantages of Rouviere's sulcus and the crucial perspective of safety as extrahepatic markers in preventing common bile duct damage. According to their research, 118 patients (39.3%) had closed type and 175 patients (58.3%) had open type. In seven (2.3%) of the cases, the sulcus was absent.

In our study, the dissection was above level of RS in 109(70%) cases and at the level of RS in 46 (30%) cases, the dissection at the level of RS was accompanied by 3 (6.5%) cases with complications, 2 (4%) cases with post-operative collection, 1 (2%) case with cystic duct stump leak.

In our study, a total of 2 (1%) cases of biliary injury, one case of biliary injury occurred in RS nonvisible in the form of CBD injury, diagnosed intraoperative and managed by hepaticojejunostomy after conversion to open. While the other case of biliary injury occurred in RS visible, the dissection was at the level of Rouviere's sulcus, the bile leak was from cystic duct stump, diagnosed postoperative and managed by ERCP with stent.

This agreed with **Kumar et al.** ⁽⁸⁾ who reported that, the total prevalence of bile duct damage (BDI) was 1 in 230 patients, or 0.4%. **Bajpayee et al.** ⁽¹²⁾ who had started the dissection ventral to the RS during laparoscopic cholecystectomy, demonstrating little common bile duct damage.

The most important risk factor for bile duct damage during laparoscopic cholecystectomy, according to 2002 research, was the surgeon's spatial disorientation. He avoided this by using empirical principles established by the aviation and marine sectors, one of which is to begin dissection from a fixed position. They discovered that Rouviere's sulcus serves as an extra biliary fixed point and is a helpful anatomical marker for this purpose ⁽¹³⁾.

In our study, the 2 cases of blood loss intra-operatively were from GB bed, managed by cauterization. The 1st case, the RS was not present, post-operatively D 0 the drain was filled with 350 cc blood, conservative management applied and in D 5 the drain was less than 50 cc serosanguinous, total amount of blood loss was 650 cc blood, and the patients needed one packed RBCs and 2 Fresh frozen plasma. The 2nd case, The Rs was not present too, in D 0 the drain was

filled with 250 cc blood, conservative management applied and at D4 the drain had less than 50 cc serosanguinous, total amount of blood loss was 450 cc blood, the patient needed one packed RBCs and 2 Fresh frozen Plasma.

In our study, due to a technical issue, only 4 cases (2%) were converted to open cholecystectomy (1 case). severe irritation and adhesion in one instance. one example of deformed anatomy and one case of biliary damage.

From 2002 to 2007, 1046 patients had laparoscopic cholecystectomy at a single facility; in 998 of those instances, the critical perspective of safety was used. 2.7% of patients had an open cholecystectomy ⁽¹⁴⁾.

Elwan ⁽¹¹⁾ reported that two patients (0.7%) had an open cholecystectomy due to significant adhesions that were unsafe for laparoscopic dissection. Significant problems did not arise during or after the procedure.

This study showed that, regarding postoperative data in the study participants, collection was present in 5 (3%) participants and biliary leak in 2 (1%) participants. Postoperative wound infection occurred in 4 (2%) participants and drain was present in 148 (95%) participants.

In our research post-operatively, The RS was not present in 3 out of 5 cases with collection and the 2 other cases the dissection was at the level of RS.

In our research, Rouviere's sulcus was not present in 1 case of biliary leak which converted to open and hepaticojejunostomy was done, not present in 2 cases of blood loss and not present in 3 cases post-operative collection. Two instances of post-operative collection and one case of biliary leak in the form of cystic duct stump leaking had callosum incision at the level of RS.

Similarly, **Heistermann et al.** ⁽¹⁵⁾ using a critical perspective of safety in a research included 100 patients, who had laparoscopic cholecystectomy. Their study's objective was to demonstrate that it was possible to acquire a critical perspective on safety and to substantiate it via photographic evidence. A laparoscopic method was used to accomplish 97 out of 100 cholecystectomies, despite an elevated rate of acute cholecystitis and prior abdominal procedures, after picture recording of the crucial perspective of safety. One surgical side effect was a biliary leak caused by a ruptured cystic duct stump.

In the current study, duration of operation and length of hospitalization was substantially longer in patients whom RS were not visible than those who were visible ($p < 0.001$, $= 0.008$ respectively).

Kumar et al. ⁽⁸⁾ reported that, compared to the RS not visible group, the operative time was around 25% shorter in the RS visible group. Since RS indicates the CBD plane, there would have been no time spent on adhesion release in the RS visible group, and the operating surgeons may not have been concerned about the possibility of CBD harm.

CONCLUSION

RS is an easily identifiable anatomical landmark should be well identified for safe Laparoscopic cholecystectomy. RS is recommended to be used as an extrabiliary anatomical land mark for the appropriate site, dissection of Callot above its level provides safe laparoscopic cholecystectomy.

DECLARATIONS

- **Consent for publication:** I certify that each author has granted permission for the work to be submitted.
- **Funding: No fund**
- **Availability of data and material:** Available.
- **Conflicts of interest:** no conflicts of interest.
- **Competing interests:** None.

REFERENCES

1. **Salem M, Salah E, Abdel-Hady W, Abdallah E (2023):** Assessment of Risk Factors for Conversion from Laparoscopic Cholecystectomy to Open Cholecystectomy. *The Egyptian Journal of Hospital Medicine*, 91(1): 4821-4827.
2. **Reinsoo A, Kirsimägi Ü, Kibuspuu L et al. (2023):** Bile duct injuries during laparoscopic cholecystectomies: an 11-year population-based study. *Eur J Trauma Emerg Surg.*, 49(5), 2269-2276.
3. **Alius C, Serban D, Bratu D et al. (2023):** When Critical View of Safety Fails: A Practical Perspective on Difficult Laparoscopic Cholecystectomy. *Medicina (Kaunas)*, 59(8):1491. doi: 10.3390/medicina59081491.
4. **Manatakis D, Antonopoulou M, Tasis N et al. (2023):** Critical View of Safety in Laparoscopic Cholecystectomy: A Systematic Review of Current Evidence and Future Perspectives. *World J Surg.*, 47(3): 640-648.
5. **Sharma S, Sood R, Garg A, Anand S (2023):** Rouviere's Sulcus Analysis: A Critical Safety Analysis and a Guide to Safe Laparoscopic Cholecystectomy. *Cureus*, 15(5):e39385. doi: 10.7759/cureus.39385 .
6. **Peti N, Moser M (2012):** Graphic reminder of Rouviere's sulcus: a useful landmark in cholecystectomy. *ANZ J Surg.*, 82(5):367-8.
7. **Jha A, Dewan R, Bhaduria K (2020):** Importance of Rouviere's sulcus in laparoscopic cholecystectomy. *Ann Afr Med.*, 19(4):274-277.
8. **Kumar A, Shah R, Pandit N et al. (2020):** Anatomy of Rouviere's Sulcus and Its Association with Complication of Laparoscopic Cholecystectomy. *Minim Invasive Surg.*, 2020:3956070. doi: 10.1155/2020/3956070.
9. **Thapa P, Maharjan D, Tamang T, Shrestha S (2015):** Visualisation of Rouviere's Sulcus during Laparoscopic Cholecystectomy. *JNMA J Nepal Med Assoc.*, 53(199):188-91.
10. **Hugh T, Kelly M, Mekisic A (1997):** Rouvière's sulcus: a useful landmark in laparoscopic cholecystectomy. *Br J Surg.*, 84(9):1253-4.
11. **Elwan A (2019):** Critical view of safety and Rouviere's sulcus: Extrahepatic biliary landmarks as a guide to safe laparoscopic cholecystectomy. *The Scientific Journal of Al-Azhar Medical Faculty, Girls*, 3(2): 297-301.
12. **Bajpayee P, Neelesh Kanaskar P, Manivikar P (2021):** Significance of Rouviere's Sulcus in Hepatobiliary Surgery: A Cadaveric study. *Int J Anat Res.*, 9(3.2): 8074-78.
13. **Pathak R, Mittal L, Chouhan G, Tripathi A (2023):** Rouviere's Sulcus: A Guide to Safe Laparoscopic Cholecystectomy. *Journal of Acute Care Surgery*, 13(1): 10-12.
14. **El-Saman B, Lasheen A, Abdelaty W (2022):** Role of Rouviere's sulcus in identification and dissection of Calot's triangle during Laparoscopic Cholecystectomy. *Al-Azhar International Medical Journal*, 3(12): 186-194.
15. **Heistermann H, Tobusch A, Palmes D (2006):** Prevention of bile duct injuries after laparoscopic cholecystectomy." The critical view of safety". *Zentralblatt für Chirurgie*, 131(6): 460-465.