

Study Of Risk Factors Associated With Allergic Fungal Sinusitis Patients: A Case-Control Study

Tarek Mohamed M. Mansour¹, Mahmoud Ibrahim M Elawamry²,

Mohammed Ahmed Hussien², Amr Embaby El-Sayed², Mohamed M. El-Baroudy³

Departments of ¹Radio-diagnosis and ²Otorhinolaryngology Faculty of Medicine, Al-Azhar University, Assuit, Egypt

Department of ³Radio-diagnosis, South Egypt Cancer Institute, Assuit University, Egypt

*Corresponding author: Tarek Mohamed M. Mansour, **Mobile:** (+20) 01006237731, **E-mail:** drtarekrad@gmail.com

ABSTRACT

Background: A non-invasive sinusitis that often affects young persons is allergic fungal sinusitis.

Objective: This study aimed to explain the potential risk factors that may affect patients suffering from nasal polyps with allergic fungal sinusitis (AFS) local anatomical variants or general illnesses.

Patients and methods: This case-control study was carried out on 160 patients (80 patients with allergic nasal polyposis with fungal sinusitis and 80 cases with nasal polyp without superimposed fungal infection). The study was performed at the ENT Department, Faculty of Medicine, Al-Azhar University, Assuit, from 21st May 2018 to 21st May 2022.

Results: The mean vitamin D level was considerably lower in the case group (27.86 ±5.92 ng/mL) than in the control group (38.98 ±5.92 ng/mL). The cases had significantly higher anatomical abnormalities (deviated nasal septum and inferior turbinate hypertrophy) than the control group (P value <0.001). MW-I was lower significantly in the case group than in the control group while ML-I was significantly longer in the case group than in the control group (P value <0.001). Deviated nasal septum, vitamin D, MW-I, and ML-I were significant independent predictors for fungal sinusitis (P value < 0.001)

Conclusions: Features of anatomical abnormalities, such as a notably deviated septum, MW-I, and ML-I may increase the incidence of fungal sinusitis more than general illness as bronchial asthma and DM. Vitamin D deficiency may have a role in developing superimposed fungal sinusitis.

Keywords: Allergic fungal sinusitis, Risk factors, vitamin D, Computed tomography.

INTRODUCTION

Young adults with prior allergy illnesses, unusually high levels of total peripheral eosinophils, and immunoglobulin E are frequently affected by allergic fungal sinusitis (AFS), a non-invasive pansinusitis [1]. The prevalence and incidence of AFS appear to be significantly influenced by sociodemographic variables. Patients who suffer from those who have chronic sinusitis are more likely to acquire AFS [2].

Although the precise pathophysiology of AFS remains unknown, one proposed theory is that fungi encountered during normal nasal inhalation are the earliest antigenic stimuli in an atopic host. Eosinophils are involved in a severe inflammatory response after a type I (IgE) and type III (immune complex) mediated reaction [2]. Certain anatomical features, such as deviated septal cartilage or hypertrophied turbinates, might promote the inflammation that blocks the ostia. When the sinus ostium is blocked, the surrounding conditions are ideal for the growth of the fungus. Allergenic mucin, produced in response to repeated antigen exposures, eventually fills the affected sinuses of an AFS patient [3].

AFS is associated with several complications, including proptosis, orbital abscesses, and occasionally vision loss. The illness and surgical intervention put important neurovascular systems at risk, such as the cranial nerves, dura mater, internal carotid artery, cerebral lobes, and cavernous sinus [4].

Although nasal polyposis is a hallmark of AFS, the condition is not definitively diagnosed until histology is performed post-operatively. Hence, it is crucial to identify the risk factors that might predict the diagnosis of AFS before surgery [5].

As the risk factors for AFS among patients with nasal polyps have not been adequately quantified, and due to the possibility of illness complication in instances of AFS, this study was designed to clarify the possible risk factors related to patients suffering from nasal polyps with fungal sinusitis locally as anatomical variants (deviated septum, inferior turbinate hypertrophy, and concha bullosa) or general illness (DM, Asthma, and Vit D insufficiency) [5].

This study aimed to explain the potential risk factors that may affect patients suffering from nasal polyps with AFS local anatomical variants or general illnesses.

PATIENTS AND METHODS

This case-control study was carried out on 160 patients (80 patients with allergic nasal polyposis with fungal sinusitis and 80 cases with nasal polyp without superimposed fungal infection). The study was performed at the ENT Department, Faculty of Medicine, Al-Azhar University, Assuit, from 21st May 2018 to 21st May 2022.

Exclusion criteria were cases younger than 18 years, invasive fungal sinusitis, nasal malignancies, genetic disorders accompanied by ciliary dysfunction, and complex sinusitis due to any reason rather than AFS.

Patients were classified as having AFS if they satisfied the primary **Bent and Kuhn's** criteria for diagnosis (the secondary indicators provide validity to the primary diagnosis) [6].

As outlined in the European position paper on chronic sinusitis, all participants met the following requirements [5]: (A) The existence of at least two symptoms; one of these symptoms should be nasal blockage/obstruction/congestion or nasal discharge (posterior/anterior/drip); facial pain/pressure; loss or reduction of smell; duration > 12 weeks. (B) Either (1) Endoscopic evidence of: polyps and/or, mucopurulent discharge predominantly from the middle meatus and/or, edema/ mucosal blockage mostly in the middle meatus, (2) and/or CT alterations: mucosal alterations in the sinuses and/or ostiomeatal complex.

All of the patients in this study underwent a thorough clinical evaluation, (including an ENT examination and an endonasal sinoscopic evaluation), radiological examination (CT of the nose and paranasal sinus, and chest X-ray), and laboratory investigations (vitamin D level, HbA1c).

CT scans was performed in all cases to look for signs of chronic sinusitis; with or without superimposed fungal infection, osteoma, turbinate hypertrophy, and nasal septal deviation.

In addition, several quantitative variables were measured in the coronal view, such as the angle of nasal septum deviation, the maximum length of the infundibulum (ML-I), which was calculated as the longest distance between the infundibular ostium and the highest point of the uncinate process (semilunar hiatus), and the minimum infundibulum width (MW-I),

which was estimated as the shortest distance between the infundibular walls [7].

ELISA for human vitamin D immunoassay was used to determine the vitamin D concentration in the blood (Calbiotech, Inc., Spring Valley, CA, USA). All of the measurements were performed by the same investigator using the same equipment in a controlled environment. The blood was centrifuged at 1250 g for 15 minutes.

Ethical approval:

Al-Azhar University Medical Ethics Committee of the Faculty of Medicine, Al-Azhar University, Assiut gave its approval to this study. All participants gave written consent after receiving all information. The Helsinki Declaration was followed throughout the study's conduct.

Statistical analysis

SPSS v27 was used for the statistical analysis. Histograms and the Shapiro-Wilks test were employed to determine whether or not the data had a normal distribution. Mean and standard deviation were used to depict quantitative parametric data (SD). Frequency and percentage were used for qualitative variables. The unpaired student t-test was used to evaluate the parametric data for the quantitative variables, while the Chi-square test or Fisher's exact test was used for the qualitative variables. Statistical significance was defined as a two-tailed P value < 0.05.

RESULTS

Demographic data and medical history were insignificantly different between both groups (**Table 2**).

Table (1): Demographic data and medical history of the studied groups

		Case group (n=80)	Control group (n=80)	P value	Mean difference / Odds ratio (95%CI)
Age (years)		29.14 ± 9.38	32.51 ± 13.25	0.065	-3.38 (-6.96:0.21)
Sex	Male	36 (45%)	29 (36.25%)	0.26	1.44 (0.76:2.71)
	Female	44 (55%)	51 (63.75%)		
Medical history	Diabetes mellitus	7 (8.75%)	1 (1.25%)	0.064	7.58 (0.91:63.07)
	Smoking	20 (25%)	26 (32.5%)	0.295	0.69 (0.35:1.38)
	Asthma	29 (36.25%)	20 (25%)	0.123	1.71 (0.86:3.37)

Vitamin D level in the case group was 27.86 (±8.46) ng/mL, whereas level in the control group was 38.98 (±5.92) ng/mL. The case group had considerably lower vitamin D levels compared to the control group (P <0.001) (**Figure 1**).

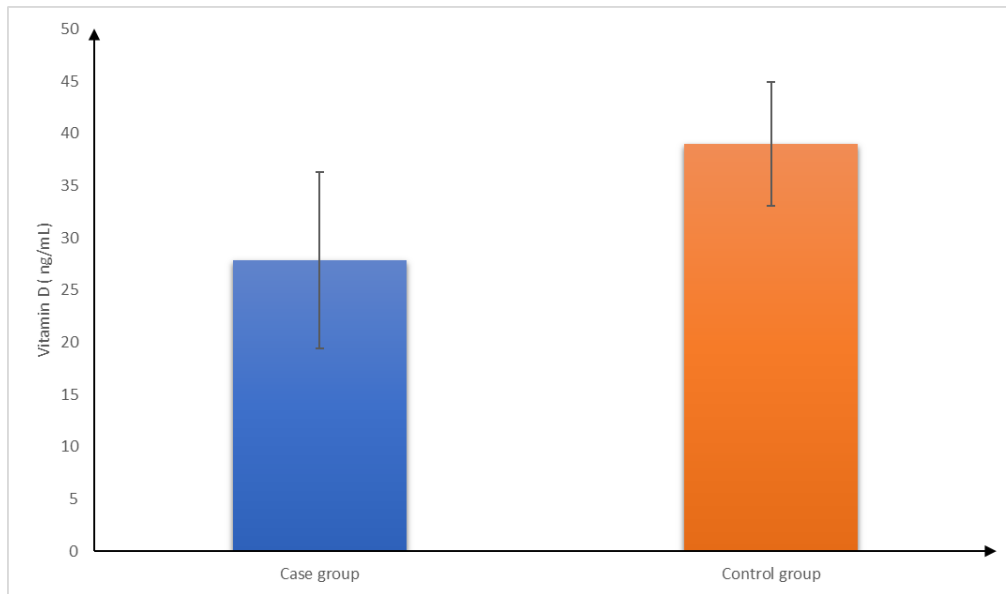


Fig. (1): Vitamin D of the studied patients

The prevalence of deviated nasal septum and inferior turbinate hypertrophy was markedly more prevalent in the case group than in the control group. The prevalence of concha bullosa was insignificantly different between both groups (Table (2)).

Table (2): Anatomical variants of the studied groups

	Case group (n=80)	Control group (n=80)	P value	Odds ratio (95%CI)
Deviated nasal septum	51 (63.75%)	14 (17.5%)	<0.001*	8.29(3.97:17.29)
Inferior turbinate hypertrophy	49 (61.25%)	23 (28.75%)	<0.001*	3.92(2.02:7.59)
Concha bullosa	8 (10%)	3 (3.75%)	0.118	2.85(0.73:11.17)

*: Significant

The case group had a significantly lower MW-I and significantly higher ML-I than in the control group. The angle of NSD was insignificantly changed between the case and the control groups (Table (2)).

Table (3): MW-I and ML-I of the studied groups

	Case group (n=80)	Control group (n=80)	P value
MW-I (mm)	3.07 ± 0.81	4.34 ± 1.38	<0.001*
ML-I (mm)	9.69 ± 1.71	8.02 ± 2.03	<0.001*
Angle of NSD (degrees)	-0.26 ± 8.55	-1.99 ± 7.89	0.185

*: Significant

Deviated nasal septum, vitamin D, MW-I, and ML-I were significant independent predictors for fungal sinusitis, while inferior turbinate hypertrophy was not (Table (4)).

Table (4): Multivariate regression analysis for prediction occurrence of fungal sinusitis

	Coefficient	Odds ratio	95% CI	P value
Deviated nasal septum	1.810	6.114	2.054 - 18.196	0.001*
Inferior turbinate hypertrophy	0.556	1.744	0.603 - 5.042	0.304
Vitamin D (ng/mL)	-0.182	0.833	0.772 - 0.899	<0.001*
MW-I (mm)	-0.955	0.386	0.235 - 0.636	0.002*
ML-I (mm)	0.464	1.591	1.190 - 2.128	0.001*

*: Significant

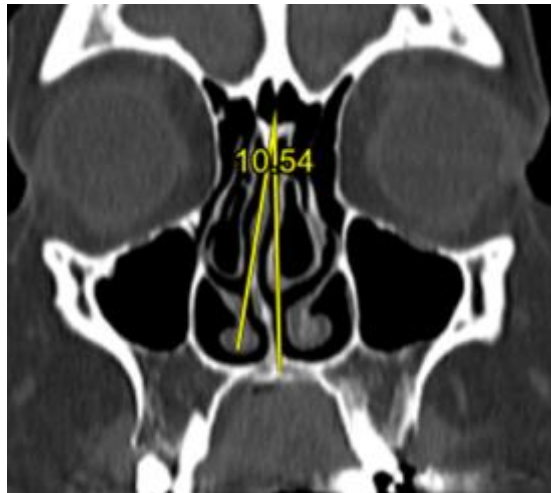


Fig. (2): Deviated nasal septum to the right side for about 10 degree associated with bilateral concha bullosa prominent at the left side

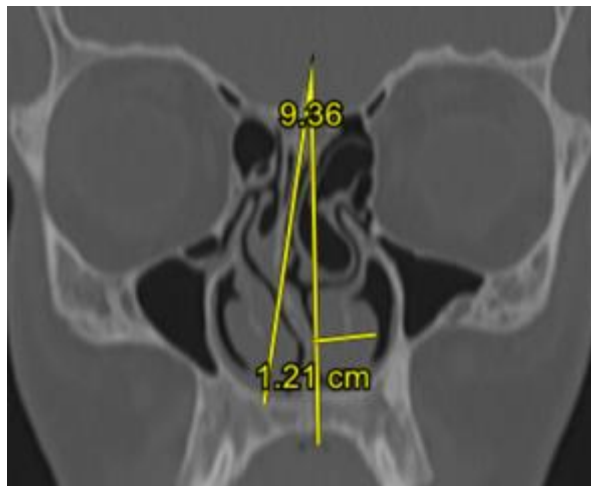


Fig. (3): Deviated nasal septum to the left side for about 9 degree associated with left concha bullosa and bilateral hypertrophied inferior nasal turbinates about 12 mm. thickness at the left side causing nasal narrowing

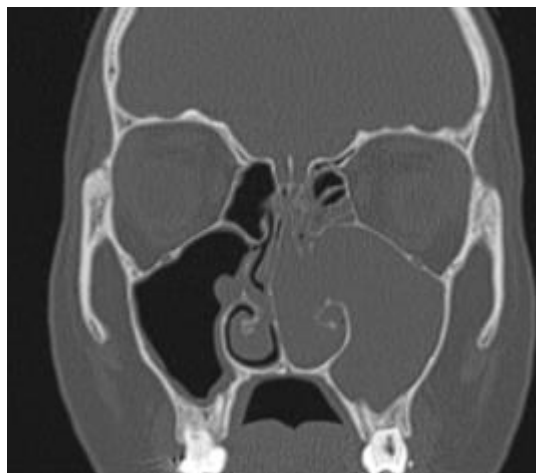

Fig. (4): Coronal bone window scan shows left antro-choanal polyp extends to the nasal cavity with right side deviated nasal septum and obliterated osteomeatal complex

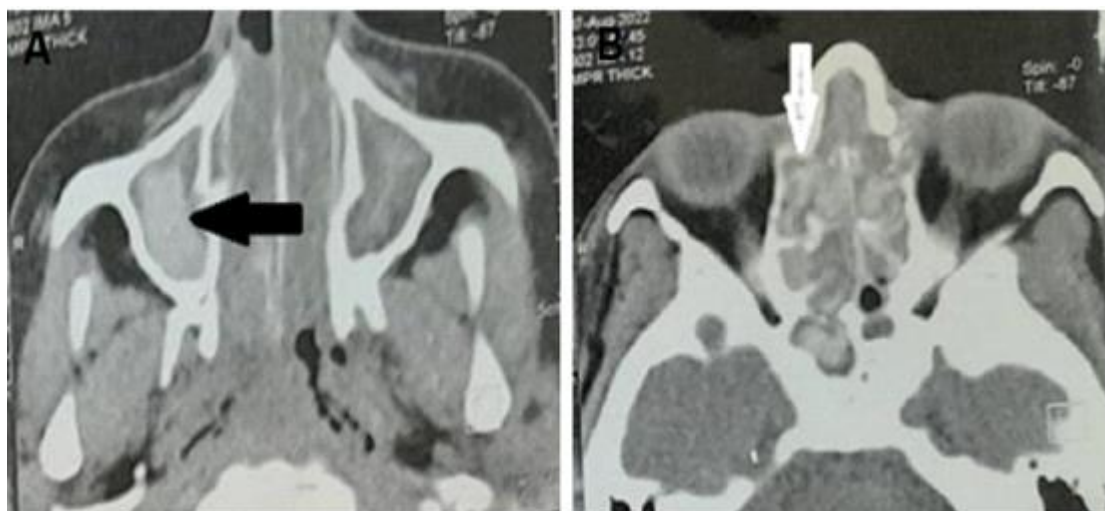


Fig. (5): Axial CT soft tissue window at the level of maxillary (A) and ethmoidal (B) sinuses shows complete opacified examined nasal sinuses with areas of hyperdenisty inside the center of the sinuses (arrow black and white) with no bony erosions. Also noted hypertrophied nasal turbinates

DISCUSSION

According to EPOS 2020, the presence of two or more symptoms, including but not limited to nasal obstruction/blockage/congestion or nasal discharge (posterior/anterior nasal drip) with or without facial pain/pressure, reduction or loss of smell, for 12 weeks identifies people as having chronic rhinosinusitis with or without nasal polyps [8]. AFS has been recognized as one of the most common forms of chronic rhinosinusitis (CRS), distinguished by a type I hypersensitivity to fungi and eosinophilic mucus containing non-invasive fungal hyphae inside the sinuses [9].

Due to the low incidence of AFS, the previously indicated general risk factors cannot account for all of its causes [9]. Our study considered anatomical variants such as the deviated nasal septum, inferior turbinate hypertrophy, and concha bullosa of middle turbinate or general illnesses such as diabetes, bronchial asthma, or low vitamin D (Fig. 2).

Our results showed that the cases group had a significantly decreased vitamin D level compared to the control group. CT scans revealed a greater prevalence of nasal anatomical changes; the case group had significantly higher deviated nasal septum and inferior turbinate hypertrophy than the control group. The case group had significantly lower MW-I with significantly longer ML-I than the control group. Deviated nasal septum, vitamin D, MW-I, and ML-I were significant independent predictors for the occurrence of AFS (Fig. 3).

Supporting our results, **Rehman et al.** [10] reported that deviation of nasal septum and turbinate hypertrophy had no significant relationship as a risk factor with AFS.

DM alters both the innate and adaptive immune system's humoral and cellular responses. Major histocompatibility complex class I expression is

downregulated. Changes are made to the complement's structure and the proportion of activation to restriction. Hyperglycemia, polymorphonuclear cell generation, neutrophil migration, chemotaxis, and phagocytic activity are all suppressed in poorly managed diabetes [11]. In addition, endothelial cell injury, fungal invasion, germination, and fast filamentous development of mucormycosis are all produced by the overexpression of the glucose-induced glucose-regulated protein (GRP) that occurs during diabetic ketoacidosis [12]. Additionally, **Fernandez et al.** [13] showed that poorly managed diabetes was a general risk factor for fungal sinusitis.

In this regard, **Nyunt et al.** [11] identified a correlation between the rising rates of diabetes and AFS among diabetic individuals. They also reported that plasma glucose level, HbA1C, and duration of diabetes were insignificantly predictors for fungal sinusitis. Moreover, **Jiang et al.** [14] demonstrated sinus fungus patients had a higher prevalence of diabetes.

In addition, a deficit in vitamin D is associated with atopic disorders, including asthma, allergic rhinitis, and anaphylaxis, negatively impacting the musculoskeletal system [15].

Vitamin D insufficiency is associated with decreased production and secretion of interleukin-4 (IL-4) and IL-10, two of the most important cytokines in type 2 immune response that are responsible for interferon-gamma production, the most crucial cytokine in type 1 immune response [16]. Vitamin D deficiency also needs greater glucocorticoid dosages to produce therapeutic benefits, suggesting that vitamin D may contribute to glucocorticoid actions on cells [18]. Thus, a weakened immune system has been associated with vitamin D deficiency, which may contribute to the aetiology of rhinosinusitis [15] (Fig. 4). **Zand et al.** [15] found that there was a substantial adverse connection

between Sino-nasal Outcome Test (SNOT-22) and vitamin D blood levels. A study by **Wang et al.** [18] found that vitamin D concentration was significantly reduced in chronic rhinosinusitis patients with nasal polyps. As a result, measuring patients' vitamin D levels as part of their standard care might provide useful information for assessing the extent of their CRs.

According to **Fernandez et al.** [13], patients with fungal sinusitis had a higher rate of anatomic nasal abnormalities shown on CT scans. The most common of the examined nasal anomalies, an anterior septum deviation that causes nasal or sinus obstruction, was the main anatomic change that is significantly associated to fungal sinusitis (Fig. 4). The abnormality in the front of the septum can cause or amplify airflow turbulence, which might then aid in the deposition of fungal spores [13]. Finally, nasal obstruction contributes to poor airflow, which in turn causes inflammation and changes in mucociliary clearance [19]. The link between the infection site and the anatomic change site in all of the cases in our study supports this concept and the unilateral beginning of AFS [13].

It was established that the anatomical variables influence the maxillary sinus (MS) mucosal thickenings and the MW-I and ML-I were the foremost risk variables in sinusitis [7]. In addition, **Shin et al.** [20] and **Alkire and Bhattacharyya** [21] found that fungal sinusitis patients had a significantly lower mean MW-I and a longer ML-I than controls.

Blockage of sinus drainage is caused by the blockage of the sinus ostium, which can be exacerbated by anatomical factors such as turbinate hypertrophy or septal deviation. The paranasal sinuses become a favorable environment for the fungus as a result [22].

The nasal cavity serves to filter out larger particles like airborne fungus spores and to humidify and warm the incoming air during inspiration [24]. The mechanics of nasal fluid flow are unclear; however, research has shown that most airflow and turbulence occur in the small space between the nasal septum and middle turbinate during normal inspiration [19,23,24]. Therefore, this spot might be the first to collect fungus spores.

This concept might explain the presence of middle turbinates at the start of the AFS course. In addition, some anatomical defects, such as anterior septum deviation, may generate or exacerbate airflow turbulence, therefore favoring the deposition of fungal spores [24,25]. Finally, the resulting nasal blockage results in reduced ventilation, inflammation, and a change in mucociliary clearance [19,23].

Our study had certain limitations because it was conducted at a single centre with a small sample size, so results may vary in other settings. To make sure the main risk factors causing AFS are identified, more research with bigger sample sizes are advised. The therapy of vitamin D insufficiency could be a solution for AFS.

CONCLUSIONS

The presence of anatomical variations, such as marked septal deviation and concha bullosa, may increase the incidence of AFS more than general illness, as bronchial asthma and diabetes mellitus may be due to improper drainage in local causes. Vitamin D deficiency may have a role in developing superimposed AFS.

REFERENCES

1. **Chakrabarti A, Rudramurthy S, Panda N et al. (2015):** Epidemiology of chronic fungal rhinosinusitis in rural India. *Mycoses*, 58:294-302.
2. **Lionakis M, Drummond R, Hohl T (2023):** Immune responses to human fungal pathogens and therapeutic prospects. *Nat Rev Immunol.*, 23(7):433-452.
3. **Bakht Zada E, Habib M, Iqbal Z et al. (2020):** Study to determine the incidence of allergic fungal sinusitis among patients with nasal polyps and its related risk factors. *Pakistan Journal of Medical & Health Sciences*, 7: 1860-1863.
4. **Vashishth A (2015):** Extensive allergic fungal rhinosinusitis: Ophthalmic and skull base complications. *Indian J Otolaryngol Head Neck Surg.*, 67: 227-33.
5. **Hussein A, Obaid A, Lotfi W et al. (2019):** Prevalence, demographic and environmental factors of allergic fungal sinusitis among chronic sinusitis patients with nasal polyps in western Saudi Arabia. *Pan Arab J Rhinol.*, 9:26-30.
6. **Bent J, Kuhn F (1994):** Diagnosis of allergic fungal sinusitis. *Otolaryngol Head Neck Surg.*, 111: 580-8.
7. **Betin-Noriega C, Urbano-del Valle S, Saldarriaga-Naranjo C et al. (2023):** Analysis of risk variables for association with maxillary sinus mucosal thickenings: a cone-beam computed tomography-based retrospective study. *Surgical and Radiologic Anatomy*, 45: 417-29.
8. **Domínguez-Sosa M, Cabrera-Ramírez M, Marrero-Ramos M et al. (2023):** Real-life effectiveness of mepolizumab in refractory chronic rhinosinusitis with nasal polyps. *Biomedicines*, 11(2): 485. <https://doi.org/10.3390/biomedicines11020485>
9. **AlQahtani A, Alim B, Almudhaibery F et al. (2022):** The impact of climatic, socioeconomic, and geographic factors on the prevalence of allergic fungal rhinosinusitis: A worldwide ecological study. *Am J Rhinol Allergy*, 36: 19458924211069226. DOI:10.1177/19458924211069226
10. **Rehman A, Haq I, Qadree S et al. (2009):** Frequency of allergic fungal sinusitis in patients with nasal polyps and associated risk factors. *Pak J Med Health Sci.*, 3:99-102.
11. **Nyunt T, Mullol J, Snidvongs K (2021):** Predictive factors for invasive fungal rhinosinusitis in diabetic patients: Systematic review and data re-analysis. *Asian Pac J Allergy Immunol.*, 39: 1-8.
12. **Liu M, Spellberg B, Phan Q et al. (2010):** The endothelial cell receptor GRP78 is required for mucormycosis pathogenesis in diabetic mice. *J Clin Invest.*, 120: 1914-24.

13. **Fernandez I, Stanzani M, Tolomelli G *et al.* (2011):** Sinonasal risk factors for the development of invasive fungal sinusitis in hematological patients: Are they important? *Allergy Rhinol.*, 2: 6-11.
14. **Jiang T, Zhang Q, Li C *et al.* (2023):** Clinical characteristics of sphenoid sinus fungus ball: A nine-year retrospective study of 77 cases. *The Laryngoscope*, 23. doi: 10.1002/lary.30683.
15. **Zand V, Baradaranfar M, Vaziribozorg S *et al.* (2020):** Correlation of serum vitamin D levels with chronic rhinosinusitis disease severity. *Iran J Otorhinolaryngol.*, 32: 35-41.
16. **Ozkara S, Keles E, Ilhan N *et al.* (2012):** The relationship between Th1/Th2 balance and 1 α ,25-dihydroxyvitamin D in patients with nasal polyposis. *Eur Arch Otorhinolaryngol.*, 269: 2519-24.
17. **Searing D, Zhang Y, Murphy J *et al.* (2010):** Decreased serum vitamin D levels in children with asthma are associated with increased corticosteroid use. *J Allergy Clin Immunol.*, 125: 995-1000.
18. **Wang L, Lee C, Chien C *et al.* (2013):** Serum 25-hydroxyvitamin D levels are lower in chronic rhinosinusitis with nasal polyposis and are correlated with disease severity in Taiwanese patients. *Am J Rhinol Allergy*, 27: 162-65.
19. **Zhao K, Dalton P (2007):** The way the wind blows: implications of modeling nasal airflow. *Curr Allergy Asthma Rep.*, 7: 117-25.
20. **Shin J, Baek B, Byun J *et al.* (2016):** Analysis of sinonasal anatomical variations associated with maxillary sinus fungal balls. *Auris Nasus Larynx*, 43:524-8.
21. **Alkire B, Bhattacharyya N (2010):** An assessment of sinonasal anatomic variants potentially associated with recurrent acute rhinosinusitis. *Laryngoscope*, 120:631-4.
22. **Makihara S, Kariya S, Naito T *et al.* (2019):** Low incidence of allergic fungal rhinosinusitis in Japanese patients. *Clin Med Insights Ear Nose Throat.*, 12: 1179550619870758. doi: 10.1177/1179550619870758
23. **Wolf M, Naftali S, Schroter R *et al.* (2004):** Air-conditioning characteristics of the human nose. *J Laryngol Otol.*, 118: 87-92.
24. **Grutzenmacher S, Robinson D, Grafe K *et al.* (2006):** First findings concerning airflow in noses with septal deviation and compensatory turbinate hypertrophy--a model study. *ORL J Otorhinolaryngol Relat Spec.*, 68: 199-205.
25. **Garcia G, Tewksbury E, Wong B *et al.* (2009):** Interindividual variability in nasal filtration as a function of nasal cavity geometry. *J Aerosol Med Pulm Drug Deliv.*, 22:139-55.