

## Feasibility and Outcomes of Total Mesocolic Excision versus Traditional Resection in Rt-Sided Colon Cancer: Review Article

Tamer Abd El-Halim Hussein Farag<sup>\*1</sup>, Soliman Hamed El-Kamash<sup>1</sup>,  
Mohamed Kamal El-Din El-Hadary<sup>1</sup>, Emad Hokam<sup>1</sup>, Hamdy Mohamed Shaban<sup>1</sup>

<sup>1</sup>Department of General Surgery, Faculty of Medicine, Suez Canal University

\*Corresponding author: Tamer Abd El-Halim Hussein Farag

Mobile: +201015603529, E-mail: [Dr.tamerfarag@gmail.com](mailto:Dr.tamerfarag@gmail.com)

### ABSTRACT

As per the GLOBOCAN database of the World Health Organization, colorectal cancer (CRC) ranks 3<sup>rd</sup> among males and second among females in terms of frequency of diagnosis. Symptoms of colorectal cancer may not appear straight away. A decreased red blood cell count can be the earliest indication of colorectal cancer. Surgery, radiation treatment, and chemotherapy are all viable alternatives. The gold standard of care is surgical resection. Most cases of colon cancer are treated with potentially curative radical surgery. The fundamental concepts of surgery include detaching the primary vascular pedicle supplying the tumor and its lymphatics, achieving a tumor-free margin, and resecting the tumor as a whole along with any associated organs or tissues (end bloc resection). The local recurrence rate of right-sided cancers does not appear to be affected by ileum length. When a tumor develops in cecum, ascending colon, hepatic flexure, or proximal transverse colon, blood supply is diverted from the right branch of main colic artery to the right colic artery and ileocolic artery, respectively. When doing open surgery, doctors typically take a "lateral-to-medial" technique. First, the lateral peritoneal fold is found; this is an embryonic fusion plane that helps surgeons separate the mesofascia and retrofascia when treating right-sided colon tumors. "Standard" or "traditional" colon surgery has been used as a comparison to "complete mesocolic excision" (CME). During "standard" colon surgery, the surgeon's approach and the presence or absence of radical lymph node dissection are also variables.

**Keywords:** Total Mesocolic Excision, Traditional Resection, Colon Cancer, Outcomes.

### INTRODUCTION

It is anticipated that over 881,000 people would lose their lives to CRC in 2018. With an estimated 551,000 deaths in 2018, globally, colon cancer is positioned as the fifth most prevalent causes of death from cancer <sup>(1)</sup>.

Colorectal cancer was estimated to be the second most commonly diagnosed cancer and the second leading cause of cancer death in Europe in 2020, with nearly 520000 new cases and 245000 deaths <sup>(2)</sup>.

The occurrence of colorectal cancer is linked to several potential dangers. Age and genetics are examples of elements over which an individual has no say. The development of colorectal cancer may also be influenced by a wide range of environmental and lifestyle variables <sup>(3)</sup>.

Intestinal bleeding is a common complication of colorectal malignancies. It's possible to detect the blood in the feces or notice a change in color, but most of the time the stool appears unaffected. But the cumulative blood loss might cause a decrease in red blood cell count (anemia) over time. It is not uncommon for a low red blood cell count to be the initial indicator of colorectal cancer <sup>(4)</sup>.

The great majority of CME research done so far have been retrospective. Comparisons between CME and "standard" or "traditional" colon surgery have been made in a small number of studies. The difficulty with "standard" colon surgery lies in the fact that the procedure relies on the skill of the operating surgeon in

addition to the presence or absence of drastic lymph node dissection.

It is becoming increasingly evident that differences in oncologic results reported among surgeons are directly linked to the differences in the techniques used <sup>(5)</sup>.

In surgery, when the rectum is separated from its surrounding tissues via dissection, a surgical region known as the circumferential resection margin (CRM) is produced. A region of resection that has not been peritonized. The biggest area is found in the back of the body and tapers to a point below the lumbar vertebrae, starting at the mesocolon of the sigmoid column. The triangle becomes the circumferential boundary below the peritoneal reflection, and it extends all the way down to the skin at the base of the mesorectum <sup>(6)</sup>.

An attractive mesorectal mass characterized by a smooth, lipoma-like surface and minimal or negligible deficiencies or incisions (no deeper than five mm) is indicative of a successful and comprehensive mesorectum excision as seen from the outside in. Moderate mesorectum bulk, somewhat uneven surface, border faults, and likely a little degree of taper characterize an excision that is suboptimal or nearly complete. There is poor quality mesorectum excision when there is a tiny mesorectum mass with a very uneven surface, significant deficiencies (one cm<sup>2</sup>), or deeper incisions down to muscularis propria and/or a pronounced taper <sup>(7)</sup>.

**Colorectal Cancer (CRC)**

**Epidemiology:** Both the prevalence and death rates of CRC differ greatly between regions. Based on data from the GLOBOCAN database of the World Health Organization, colorectal cancer is identified as the 2<sup>nd</sup> most frequently diagnosed cancer in females and the 3<sup>rd</sup> most frequently diagnosed cancer in males globally. Mortality and incidence rates are significantly higher among males than among females (8).

Screening asymptomatic persons under the age of fifty is currently not recommended by most guidelines unless there is a positive family history or a predisposing genetic condition. The increased rates of early-onset CRC, especially among those aged forty to forty-nine, have led some to advocate decreasing the age at which people should begin screening in 2018 (9).

**Risk factors:** CRC is linked to a number of potential dangers. Age and genetics are examples of things that a person has no say over. Furthermore, several environmental and lifestyle risk factors may have a significant part in the progression of CRC (3).

These factors include age, socioeconomic level, personal history of inflammatory bowel illness or adenomatous polyps, as well as a family history of colorectal cancer or adenomatous polyps, and a personal history of inflammatory bowel disease. Inheritable

genetic risk, environmental risk factors, dietary habits, levels of physical activity, obesity and consumption of alcoholic beverages and tobacco products are some of the risk factors (3).

**Mechanisms "Pathophysiology" of CRC:**

When normal epithelial cells in the colon undergo the transition to adenocarcinoma, they typically undergo a series of histological changes as well as concomitant epigenetic and genetic alterations. In the 'classic' paradigm for CRC development, a polyp with an abnormal crypt gives birth to an early adenoma that grows to one cm in size and has tubular or tubulo-villous histology. Adenoma transforms into an advanced adenoma when it reaches one cm in size and/or has villous histology. This is owing to the accumulation of mutations and epigenetic modifications and typically takes about ten to fifteen years to develop, however in some cases (such as in people with Lynch syndrome) it can develop more quickly. Significantly, while the histology of conventional tubular adenomas remains relatively consistent, the molecular biology of these polyps exhibits heterogeneity. This discrepancy could potentially account for the subset of adenomas (~10% of polyps) that develop into colorectal cancer (CRC) (10) (Fig.1).

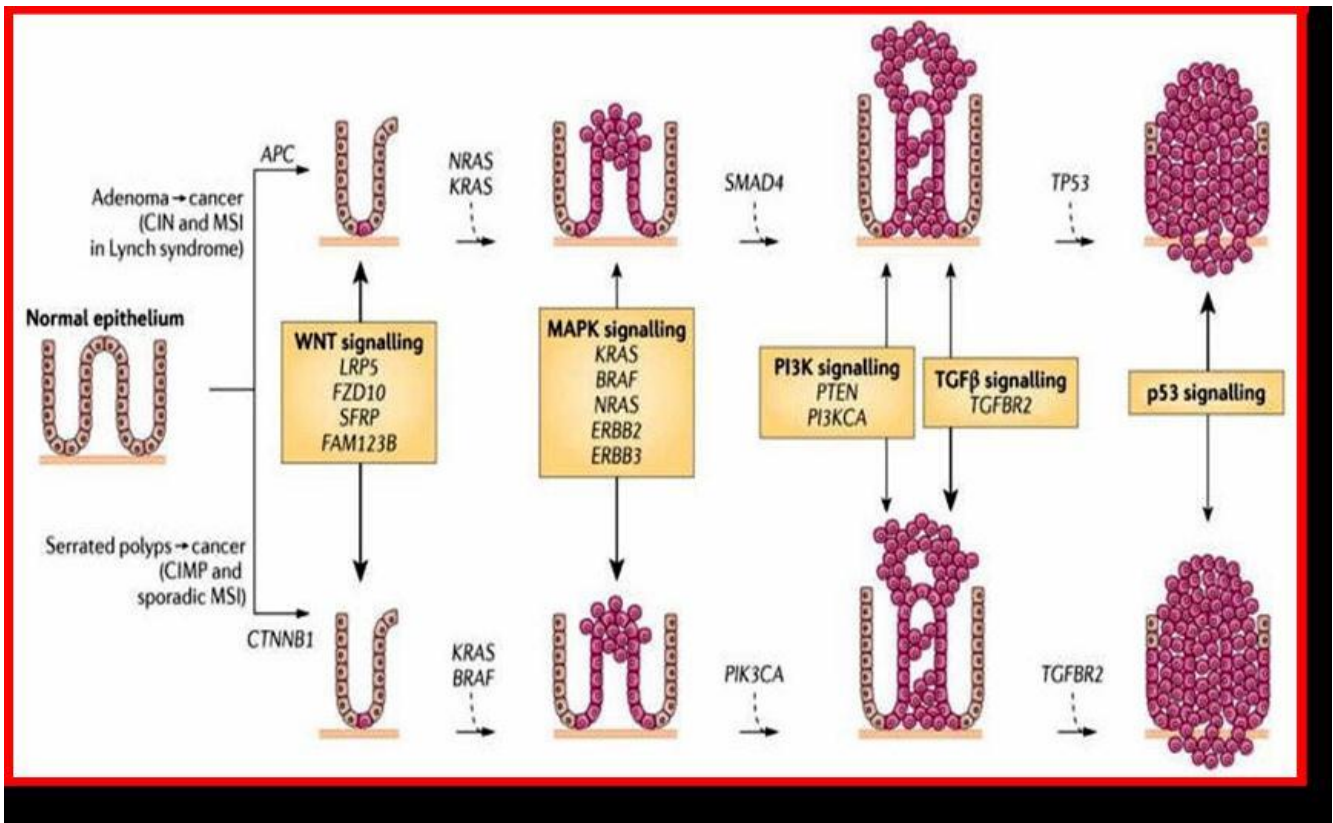


Fig. 1: The polyp to colorectal cancer sequences (11).

There is considerable variation in the specific mutations observed among CRC tumors, albeit these mutations appear to congregate in groups that are epistatically related (e.g., genes implicated in a particular signaling pathway). APC, -catenin1 (CTNNB1), KRAS, BRAF, SMAD4, TGFBR2, TP53, phosphatidylinositol-4,5-bisphosphate 3-kinase catalytic subunit-alpha (PIK3CA), AT-rich interactive domain 1A (ARID1A), SRY (sex-determining region Y), family with sequence similarity 123B (FAM123B; also known as AMER1), and ERBB2 are among the most frequently observed modifications in colorectal cancer. These modifications disrupt the operation of critical signaling pathways, among which the Wnt- $\beta$ -catenin, the epidermal growth factor (EGF)-mitogen-activated protein kinase (MAPK), phosphatidylinositol 3-kinase (PI3K), and TGF- $\beta$  signaling pathways may be targeted, or genes that regulate fundamental cellular processes such as DNA repair and proliferation may be influenced. Colorectal cancer (CRC) often arises from perturbations in the Wnt signaling pathway; subsequent neoplastic cells develop due to dysregulation of additional signaling pathways, including RAS-RAF-MAPK, TGF- $\beta$ , and the PI3K-AKT pathways <sup>(12)</sup>.

## Diagnosis of CRC

### I. Clinical presentation of CRC:

Signs of CRC may not appear immediately away, but if they do, they may include the following <sup>(13)</sup>: A shift in bowel patterns, an urgent need for a bowel movement that is not alleviated by having one, bleeding from the abdomen with brilliant red blood, the presence of blood in the excrement, abdominal (belly) cramps or discomfort, fatigue and weakness, as well as unintended weight loss.

### II. Screening:

Screening can detect polyps before they become dangerous, additionally can identify colon cancer in its initial phases, when the likelihood of a successful treatment is highest. Standardized screening and diagnostic protocols for CRC include the following <sup>(14)</sup>:

**Investigations: Laboratory investigation:** containing (Fecal occult blood test (blood stool test), Tumor M2-PK stool test, Stool DNA test and Biomarkers "tumor

markers" of CRC), **Radiologic investigations:** containing (Barium enema X-ray, CT colonography and MRI), **Endoscopic investigation:** containing (Flexible sigmoidoscopy, Colonoscopy and Capsule endoscopy), and **Tissue diagnosis of CRC (Biopsy and staging):** The stages of colon cancer are as follows: Stage 0 (Carcinoma in Situ), Stage I, Stage II (Stage IIA, Stage IIB and Stage IIC), Stage III (stage IIIA, stage IIIB and stage IIIC) and Stage IV (Stage IVA, Stage IVB and Stage IVC).

### Treatment of colorectal cancer

The extent of the cancer, where it is located, whether or not it has returned, the cases' general health, and other considerations will all play a role in determining the best course of treatment. Chemotherapy, radiation, and surgery are all viable alternatives for treatment. The gold standard of care is resection by surgery. Important adjuvant treatment techniques include systemic chemotherapy and pelvic radiation therapy <sup>(15)</sup>.

**I. Surgery for colorectal cancer:** As this is greatest prevalent method of treating cancer, it entails surgical removal of the tumor(s) in question as well as any lymph nodes in close proximity. Sometimes the rectum is removed in its entirety and a colostomy bag is placed for drainage, even though the bowel is normally resected. Stools are collected in the colostomy bag. In most cases, this is a short-term solution, but if the bowel ends cannot be joined, this may become a permanent solution. Early detection increases the likelihood that cancer can be removed surgically. Surgery can alleviate symptoms, but it won't cure cancer <sup>(16)</sup>.

**II. Surgical techniques: Open surgery:** Malignant tumors of the colon and rectum are removed by cutting off the affected section of intestine together with the supplying vascular pedicle. This leaves healthy tissue on all sides of the tumor. To perform a regional lymphadenectomy, a large portion of the mesentery must be removed. This includes the vascular pedicle and lymphatic drainage. Colorectal resections are shown in Fig. 2 and varied according to the tumor's anatomical position <sup>(15)</sup>.

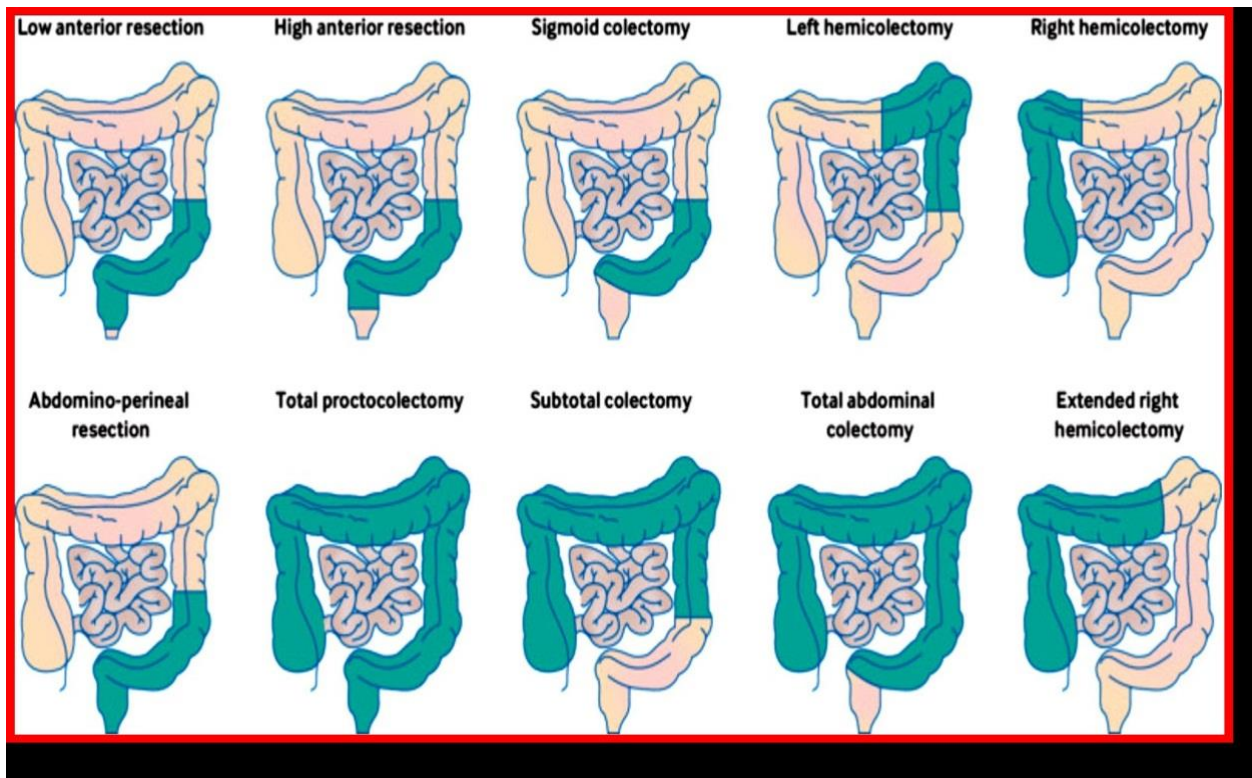


Fig 2: Diagram showing distinct CRC resections performed depending on tumor location <sup>(15)</sup>.

**Laparoscopic surgery:** The use of laparoscopic-assisted colectomy, a minimally invasive procedure, has increased in recent years for the sake of curing cancers of the colon and rectal. In this surgery, the colon is mobilized laparoscopically, as well as an extra-corporal anastomosis is created. An intra-corporal anastomosis can be done in rare cases, particularly in the low sigmoid colon. This method is used to move the mesorectum in cases of rectal cancer. The primary advantages of laparoscopic colectomy are shorter hospital stays and less need for painkillers. Results, staging, the amount of lymph nodes removed, and survival rates were all the same in past studies <sup>(17)</sup>.

**II. Adjuvant therapy:** Chemotherapy, Radiation therapy (RT) and Ablation.

**Surgical treatment of CRC:** Resection Margins, Lymphadenectomy, Obstruction and Perforation, Contiguous Organ Involvement and Hepatic Resection.

### Complete mesocolic excision (CME)

**Surgical techniques of CME:**

#### Open surgery:

When doing open surgery, doctors typically take a "lateral-to-medial" technique. First, the lateral peritoneal fold is found; this is an embryonic fusion plane that helps surgeons separate the mesofascia and retrofascia when treating right-sided colon tumors. The underlying retroperitoneum is divided from the overlying mesocolon by a solitary fascial layer, as determined histologically and anatomically (Toldt's

familia). Through the mesofascial interface, the dissection proceeds medially. In order to obtain unobstructed access to the superior mesenteric vein, superior mesenteric artery, and medially and inferiorly located superior mesenteric pedicle, the dissection proceeds over the duodenum and pancreatic uncinata process while mobilizing the mesenteric root up to its source. **Hohenberger et al.** initially delineated the inclusion of a duodenal Kocherization at this juncture; however, its implementation is not customary. From the retroperitoneum and underlying fascia, as one moves medially, the small intestinal mesentery, ileocecal junction, right colon, right mesocolon, and mesenteric confluence become wholly detached and mobilized. The maintenance of the autonomic nervous plexus is accomplished <sup>(18, 19)</sup>.

#### Laparoscopic surgery:

There is a preference for a "medial-to-lateral" strategy in laparoscopic surgery. A laparoscopic right hemicolectomy involves cutting the mesocolon close to the superior mesenteric vein, following the mesenteric axis. As near to the superior mesenteric vein as feasible, the ileocolic veins are cut. The pancreatic head and the transverse colon are widely separated once the mesocolic interface has been exposed. The gastrocolic trunk of Henle is subsequently exposed by continuing the dissection along the superior mesenteric vein. The superior mesenteric artery is located, and its right branch, the middle colic artery, is cut at its origin. Lymph nodes are also removed, with the left branch of



the main colic artery being carefully protected. The middle colic vein is located and cut at the same time <sup>(17)</sup>.

Proceeding in an anterior-to-median direction, the right side of the greater omentum is dissected. The fusion fascia is severed among the omentum and the transverse mesocolon and the hepatic flexure <sup>(20,21)</sup>.

**Outcome of CME: Surgical and pathological outcomes:** An inter-institutional comparison between Hillerod Hospital, where surgeons participated in a surgical educational training program in CME was performed, as well as six Danish institutions that focused on "traditional" surgery. Predictedly, the resection specimens obtained from the latter center displayed an increased lymph node harvest and a more pronounced mesenteric surface <sup>(5)</sup>.

#### **Oncological outcomes:**

Most recently, a retrospective population research in Denmark contrasted the outcomes for 1031 individuals who were treated with colectomies against 364 patients who received CME. Overall, the disease-free survival percentage at 4 years was 85.8 percent for cases who underwent CME and 75.9 percent for those who underwent non-CME surgery <sup>(22)</sup>.

#### **Resection lines:**

**1. The proximal resection line:** It is highly unusual to resect the tumor line at its proximal location because the proximal resection border is so large (Resections of the colon typically exceed fifteen cm in length, necessitating proximal closure of the mesenteric inferior artery). The proximal resection line is established after thinking about the flow, or the different types of blood supply <sup>(6)</sup>.

**2. The distal resection line:** The tumor is close to the dentate line makes the distal resection line more important in rectal cancer. There are 3 components of the spread to bear in mind: intramural, extramural, and lymphatic. Cancer that has spread within the lining of the rectum is extremely unusual. Over ninety-five percent of the time, it doesn't extend more than one to two centimeters past the visible endoluminal tumor. In most situations, distances from the distal mural safe limit in this range will suffice <sup>(23)</sup>.

**3. The circumferential resection line:** In surgery, when the rectum is separated from its surrounding tissues via dissection, a surgical region known as the circumferential resection margin (CRM) is produced. A region of resection that has not been peritonized. When seen from the back, the greatest area is a sloping triangle that widens from the mesocolon of the sigmoid column at its top to the tailbone at its base. The triangle transforms into the circumferential border beneath the peritoneal reflection as well extends to the mesorectum's base and the epidermis <sup>(6)</sup>.

**Level of proximal vascular ligation:** Proximal lymphovascular ligation at the site of origin is the cutting edge; rectalis superior suffices for the majority of recurrent carcinomas. The technique of adaptive lymphadenectomy involves ligation of the principal vascular branches. There is no proven advantage of high ligation of the art mesentericainferior at its origin. Removal of lymph cortex up to the major bloodstream sources appears to be sufficient in rectal cancer in the absence of clinically worrisome lymph nodes (L.N) involvement. For rectal cancer, this is where the science first began. rectalis superior, distant to the point where the left colic artery branches out <sup>(19)</sup>.

#### **Dissection of the lateral lymph node:**

L.N in the mesorectum end-bloc are removed during TME. Ten percent to thirty percent of individuals with locally advanced carcinomas will also have lymph node involvement in the lateral pelvic region. With the advent of neoadjuvant treatment, the local recurrence rate drops to below ten percent in Europe and North America, where lateral lymph node metastases are regarded distant metastases. Dissection of the lateral lymph nodes is routine in Asian medicine since their presence is seen as signifying regional lymph node involvement. The value of such a dissection, however, is debatable. In addition to mesorectum excision, routine extended lateral lymphadenectomy is not supported by sufficient data. If possible and safe to do so surgically, lymph nodes in the pelvic sidewalls that are clinically suspicious should be excised or biopsied for staging <sup>(24)</sup>.

The term "coning" is used to describe tapered look of a specimen of surgical resection caused by the surgeon's proclivity to slice the rectum wall downward during distal dissection. When operating, surgeons should avoid cutting into the visceral mesothelial fascia <sup>(25)</sup>.

#### **Macroscopic assessment of mesorectal excision:**

An appealing mesorectal mass characterized by a smooth, lipoma-like surface and minimal or negligible fissures or defects (no deeper than five mm) is indicative of a successful and comprehensive mesorectum excision as seen from the side. A considerable mesorectum mass with some irregularity on the surface, some border faults, and likely some modest taper characterizes suboptimal/nearly complete excision. Small mesorectum mass with extremely uneven surface, significant flaws (one cm<sup>2</sup>), deeper incisions down to the muscularis propria, and/or a pronounced taper are all signs of a poor-quality mesorectum excision <sup>(7)</sup>.

Understanding the embryologic fusion fascia of Fredet is essential for achieving CME, a D3-L in right colon tumors, and doing so may significantly lessen likelihood of intraoperative difficulties. Fascia of Fredet is significant anatomical landmark for colorectal

surgeons to be aware of because of the structure's use in laparoscopic procedures <sup>(26)</sup>.

## DECLARATIONS

- **Consent for publication: I certify that all the authors have given their final approval for publication.**
- **Funding: No fund**
- **Availability of data and material: Available**
- **Conflicts of interest: No conflicts of interest.**

## REFERENCES

1. **Driss A, Cécile P, Magali B et al. (2015):** Trends in colorectal cancer mortality in Europe: Retrospective analysis of the WHO mortality database. Doi: 10.1136/bmj.h4970.
2. **Cardoso, R, Guo, F, Heisser, T et al. (2021).** Colorectal cancer incidence, mortality, and stage distribution in European countries in the colorectal cancer screening era: an international population-based study. *The Lancet Oncology*, 22(7): 1002-1013.
3. **Gausman V, Dornblaser D, Anand S et al. (2020):** Risk factors associated with early-onset colorectal cancer. *Clinical Gastroenterology and Hepatology*, 18(12): 2752-2759.
4. **Bohorquez M, Sahasrabudhe R, Criollo A et al. (2016):** Clinical manifestations of colorectal cancer patients from a large multicenter study in Colombia. *Medicine*, 95(40): 1-6.e4883. doi: 10.1097/MD.0000000000004883..
5. **Bertelsen C, Neuenschwander A, Jansen J et al. (2016):** Short-term outcomes after complete mesocolic excision compared with 'conventional' colonic cancer surgery. *Br J Surg.*, 103(5):581-589. doi: 10.1002/bjs.10083.
6. **Delibegovic S (2017):** Introduction to total mesorectal excision. *Med Arch.*, 71(6):434-438. doi: 10.5455/medarh.2017.71.434-438.
7. **Jia A, Narang A, Safar B et al. (2019):** Sequential short-course radiation therapy and chemotherapy in the neoadjuvant treatment of rectal adenocarcinoma. *Radiat Oncol.*,14(147):1-6. doi: 10.1186/s13014-019-1358-1.
8. **Aran V, Victorino A, Thuler L, Ferreira C (2016):** Colorectal cancer: epidemiology, disease mechanisms and interventions reduce onset and mortality. *Clin Colorectal Cancer*, 15(3):195-203.
9. **Bénard, F, Barkun, A. N, Martel, M et al. (2018).** Systematic review of colorectal cancer screening guidelines for average-risk adults: Summarizing the current global recommendations. *World journal of gastroenterology*, 24(1), 124.
10. **Hassen S, Ali N, Chowdhury P (2012):** Molecular signaling mechanisms of apoptosis in hereditary non-polyposis colorectal cancer. *World J Gastrointest Pathophysiol.*, 3(3):71-9.
11. **Gupta S, Balasubramanian B, Fu T et al. (2012):** Polyps with advanced neoplasia are smaller in the right than in the left colon: implications for colorectal cancer screening. *Clin Gastroenterol Hepatol.*, 10(12):1395-1401.e2.
12. **Linnekamp J, Wang X, Medema J et al. (2015):** Colorectal cancer heterogeneity and targeted therapy: a case for molecular disease subtypes. *Cancer Res.*, 75(2):245-9.
13. **Xi Y, Xu P (2021):** Global colorectal cancer burden in 2020 and projections to 2040. *Transl Oncol.*, 14(10):1-7.101174. doi: 10.1016/j.tranon.2021.101174.
14. **De-Rosa M, Pace U, Rega D et al. (2015):** Genetics, diagnosis and management of colorectal cancer (Review). *Oncol Rep.*, 34(3), 1087-1096.
15. **Brown K, Solomon M, Mahon K, O'Shannassy S (2019):** Management of colorectal cancer. *Bmj.*, 366:l4561. Doi:10.1136/bmj.l4561.
16. **Matsuda T, Yamashita K, Hasegawa H et al. (2018):** Recent updates in the surgical treatment of colorectal cancer. *Ann Gastroenterol Surg.*, 2(2):129-136.
17. **She W, Poon J, Fan J et al. (2013):** Outcome of laparoscopic colectomy for cancer in elderly patients. *Surg Endosc.*, 27(1):308-12.
18. **Hohenberger W, Weber K, Matzel K et al. (2009):** Standardized surgery for colonic cancer: complete mesocolic excision and central ligation--technical notes and outcome. *Colorectal Dis.*, 11(4):354-64; discussion 364-5.
19. **São-Julião G, Habr-Gama A, Vailati B et al. (2017):** New strategies in rectal cancer. *Surg Clin North Am.*, 97(3):587-604. doi: 10.1016/j.suc.2017.01.008.
20. **Kennedy R, Francis E, Wharton R et al. (2014):** Multicenter randomized controlled trial of conventional versus laparoscopic surgery for colorectal cancer within an enhanced recovery programme: EnROL. *J Clin Oncol.*, 32(17):1804-11.
21. **Metwally I, Shetiwy M, Elalfy A et al. (2018):** Epidemiology and survival of colon cancer among Egyptians: a retrospective study. *J Coloproctol (Rio J)*, 38(1):24–29. <https://doi.org/10.1016/j.jcol.2017.09.418>.
22. **Bertelsen C, Neuenschwander A, Jansen J et al. (2015):** Disease-free survival after complete mesocolic excision compared with conventional colon cancer surgery: a retrospective, population-based study. *Lancet Oncol.*, 16(2):161-168.
23. **Dickson E, Penna M, Cunningham C et al. (2019):** Carbon dioxide embolism associated with transanal total mesorectal excision surgery: A report from the International Registries. *Dis Colon Rectum.*, 62(7):794-801.
24. **Nesgaard J, Stimec B, Bakka A et al. (2019):** Right colectomy with extended d3 mesenterectomy: anterior and posterior to the mesenteric vessels. *Surg Technol Int.*, 35:138-142
25. **Longchamp G, Meyer J, Christou N et al. (2020):** Total mesorectal excision with and without lateral lymph node dissection: a systematic review of the literature. *Int J Colorectal Dis.*, 35(7):1183-1192.
26. **Lacy A, Tasende M, Delgado S et al. (2015):** Transanal total mesorectal excision for rectal cancer: Outcomes after 140 Patients. *J Am Coll Surg.*, 221(2):415-23.