

## Surgical Outcome and Prognostic factors for Posterior Decompression of Calcified Herniated Thoracic Disc

Ahmed M. Deabes\*, Mohammed Ahmed Mourad, and Ramy Toema

Department of Neurosurgery, Benha University, Faculty of Medicine

Corresponding author: Ahmed M. Deabes, MD, Mobile: +201025001475, E-mail: [ahmed.elsayed@fmed.bu.edu.eg](mailto:ahmed.elsayed@fmed.bu.edu.eg)

### ABSTRACT

**Background:** Thoracic disc herniation accounts for only 0.15 to 1.8% of all spinal herniated discs. Usually present between the third and sixth decades with a female predilection. **Objectives:** To describe the surgical outcome and prognostic factors of post-decompression without fixation in CTDs. **Patient and methods:** from October 2016 to July 2019, a series of 9 patients with a CTD with demographic data, presentation, imaging findings, operative details, degree of spinal stenosis, duration of symptoms and outcomes using ASIA scale or mFAC. **Results:** All patients presented with at least one sign of myelopathy. Simple laminectomy was performed, and follow-up was in 1st week and 6th month. In 1st week, according to ASIA grade improved in 4 (44, 4%), stationary in 3 (33.3%), deteriorated in 2 (22.2%) patients. According to ambulation, non-ambulatory in 3 (33.3%) and independent in 5 (66.6%) patients. In 6th month, according to ASIA grade improved in 5 (62.5%), stationary in 2 (25%), deteriorated in 1 (12.5%) patient. According to ambulation, non-ambulatory in 1 (12.5%), independent in 3 (37.5%) and walker in 4 (50%) patients, one patient is missed in the 6th-month follow-up. Prognostic factors affected the surgical outcome, including the degree of spinal canal stenosis and duration of symptoms.

**Conclusions:** Posterior decompression without instrumentation allowed us to decompress the compromised spinal cord. Results overall are good with the majority of patients improving at least 1 ASIA scale or mFAC. Better outcomes were affected with less degree of spinal stenosis and less duration of symptoms

**Keywords:** Giant calcified thoracic disc herniation, Myelopathy, Simple posterior decompression.

### INTRODUCTION

Only around 0.15–1.8% of all intervertebral disc diseases are treated surgically, and of those, only about 1% are herniated thoracic discs (HTDs) that cause symptoms<sup>(1)</sup>. It has been estimated that between 7 and 15% of cases are subclinical<sup>(2)</sup>. The primary site is between the thoracic T8 and the lumbar spine's L1<sup>(2,3)</sup>. In patients above the age of 17, a calcified disc herniation occurs in over 40% of instances. If the herniated disc takes up more than 40% of the spinal canal, it is considered to be a large herniation<sup>(4,5)</sup>. Acute traumatic non-calcified disc prolapse is the most prevalent kind of thoracic disc herniation in younger patients, but calcification of the herniated disc is common in older patients with a gradual degenerative process<sup>(6)</sup>. Calcified thoracic discs (CTDs) provide difficulties for neurosurgeons due to their size, consistency, and degree of cord compression, even though spontaneous regression has been reported in certain cases<sup>(4,5)</sup>. The literature documents a variety of methods for dealing with thoracic disc herniation. There is no one best method since every strategy has pros and downsides. Trans-pedicular, trans-facet pedicle-sparing, costo-transversectomy, trans-thoracic transpleural, and thoracoscopic techniques are described<sup>(7,8)</sup>.

In terms of surgical methods, laminectomy was advocated by Brauge *et al.*<sup>(9)</sup> because it may stabilize the patient's neurologic condition in very uncommon instances of acute myelopathy caused by TDH. Hernia excision with an anterior technique is the last resort.

The purpose of this study was to analyze the effectiveness of simple posterior decompression for our patients with herniated thoracic disc that had calcified. The size and calcification of the herniated disc

contribute significantly to the degree of surgical difficulties. Since these people often arrive with myelopathy after their spinal cord has already been damaged.

### PATIENTS AND METHODS

In this retrospective analysis, we analyzed data from all patients who had excision of a calcified thoracic disc at the Neurosurgery Department, Benha University Hospitals between October 2016 and July 2019. **Table (1)** showed the patient's clinical presentation, including their pre- and post-operative American Spinal Injury Association Impairment Scale (ASIA) score, and **Table (2)** showed their ambulation status according to the modified Functional Ambulatory Category (mFAC) score, as well as the surgical procedure, recovery time, and any complications that may have arisen. Clinical outcomes after surgery were documented, collected, and statistically assessed, including postoperative ambulation and ASIA at one week and six months, as well as death.

**Inclusion criteria:** Patients were considered for inclusion if they met all three of the following criteria: (a) clinical and/or radiographic evidence of myelopathy, (b) a calcified herniation of the thoracic spine and (c) therapy with a simple laminectomy. **Exclusion criteria:** (a) Patients with a non-calcified thoracic disc and (b) patients who had procedures other than a simple laminectomy. Patient's demographic information, medical history, and how long they suffered from their symptoms before surgery were all acquired from their medical records, and the extent to which their canals were encroached upon was determined using pre-operative magnetic resonance imaging (MRI).

Calcification was confirmed as an intra-operative finding during surgery, thus pre-operative CT images were reevaluated to ensure accuracy.

**Table (1):** ASIA impairment scale <sup>(1)</sup>

Grade	Description
<b>A</b>	<b>Complete injury.</b> No motor or sensory function is preserved in the sacral segments S4 or S5.
<b>B</b>	<b>Sensory incomplete.</b> Sensory but not motor function is preserved below the level of injury, including the sacral segments.
<b>C</b>	<b>Motor incomplete.</b> Motor function is preserved below the level of injury, and more than half of muscles tested below the level of injury have a muscle grade less than 3 (see muscle strength scores table).
<b>D</b>	<b>Motor incomplete.</b> Motor function is preserved below the level of injury and at least half of the key muscles below the neurological level have a muscle grade of 3 or more.
<b>E</b>	<b>Normal.</b> No motor or sensory deficits, but deficits existed in the past.

**Table (2):** Modified Functional Ambulatory Category <sup>(10)</sup>

Category stage	Description
I <b>Lyre</b>	Patient who is unable to sit for 1 min without back and hand for support.
II <b>Sitter</b>	Patient who is able to sit for 1 min without back and hand for support. Patient cannot walk, or requires help of two or more people.
III <b>Dependent walker</b>	Patient requires firm continuous support from one person who helps carrying weight and with balance
IV <b>Assisted walker</b>	Patient needs continuous or intermittent support of one person to help with balance or coordination
V <b>Supervised walker</b>	Patient requires verbal supervision or standby help from one person without physical contact
VI <b>Indoor walker</b>	Patient can walk independently on level ground, but requires help on stairs, slopes, or uneven surfaces.
VII <b>Outdoor walker</b>	Patient can walk independently anywhere

**Ethical approval:**

**Detailed informed consent about the study was obtained from every patient. Approval was obtained from Benha University Institutional Review Board. The Declaration of Helsinki, the code of ethics of the World Medical Association, was followed when conducting this research on humans.**

**Statistical analysis**

The data were recorded on an “Investigation report form”. These data were tabulated, coded then analyzed using the computer program SPSS (Statistical package for social science) version 26. Descriptive statistics were calculated for the data in the form of Mean and Standard deviation ( $\pm$ SD). In the statistical comparison between the different groups, the significance of difference was tested using paired *t*-test, ANOVA (analysis of variance) For continuous non-parametric data, Manthen-Whitney *U*-test was used for inter-group analysis, and *P* value <0.05 was considered statistically significant.

**RESULTS**

Patients ranged in age from 47 to 67 with a mean of  $58.6 \pm 4.3$  years old and a gender split of 5 women (55.5% of the total) and 4 men (44.5% of the total). A total of four patients had a stenosis > 40%, while the remaining five patients had a stenosis < 40%. Within the first year following their first presentation, four patients had surgery, and another five did so after the first year had passed. One patient had a double calcified thoracic disc at T1-2 and T2-3, three patients experienced compression at T11-12, two patients at T7-8, two patients at T9-10, and one patient at T8-9. Four individuals also had hypertrophy of the ligamentum flavum.

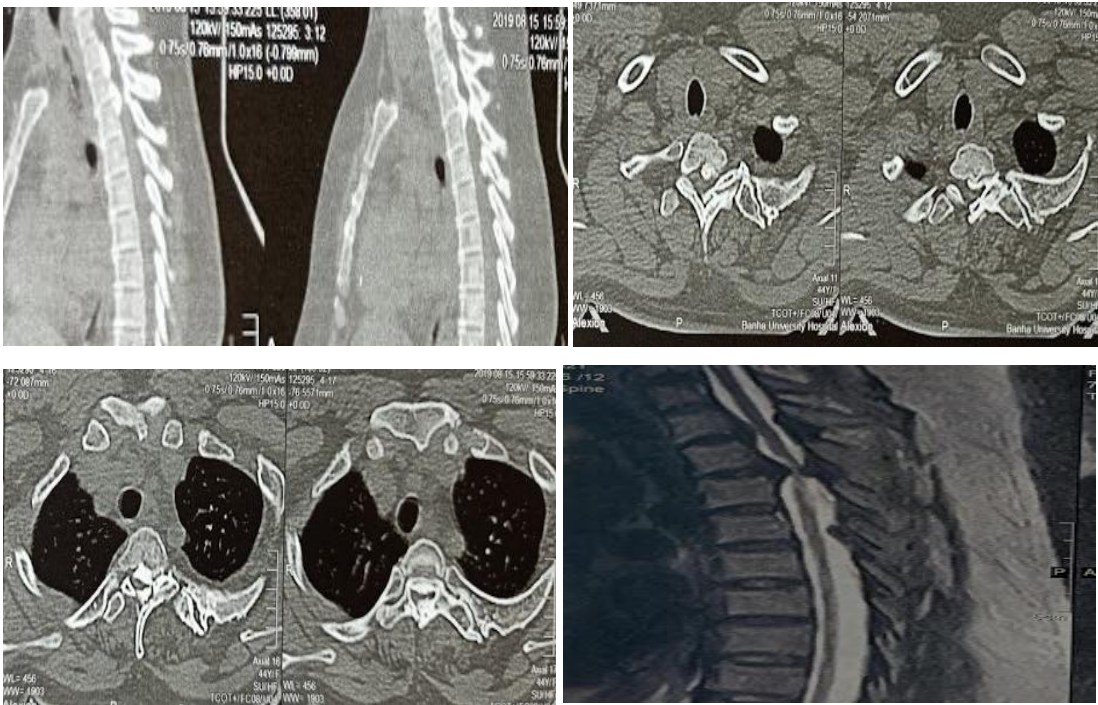
**Operative data:** all patients were operated on with simple posterior decompression without fixation and without curettage of the calcified disc.

**Clinical outcome:** One patient fulfilled preoperative ASIA-B criteria, five patients met ASIA-C criteria, and three patients met ASIA-D criteria. Clinical criteria were satisfied by 2 patients for mFAC category II, 4 patients for mFAC category III, 2 patients for mFAC category V, and 1 patient for mFAC category IV.

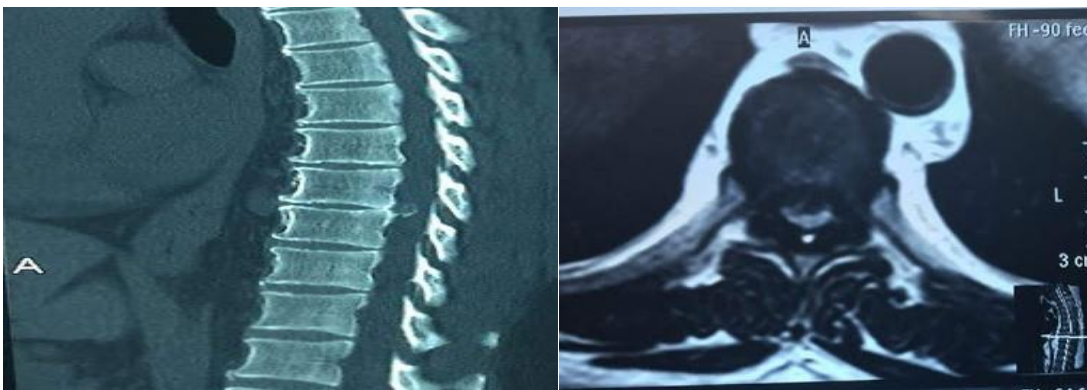**Location of Disc Herniation:**

Compression was mostly lateral in three instances, central in four, and mixed in two. Figure (1) showed CT and MRI scans that were indicative of a patient who had central and lateral compression with double-level stenosis. Figure (2) depicted the stereotypical appearance of an isolated central compression. Figure (3) showed CT images taken after surgery to monitor a patient with double-level stenosis (D1 & D2-3).

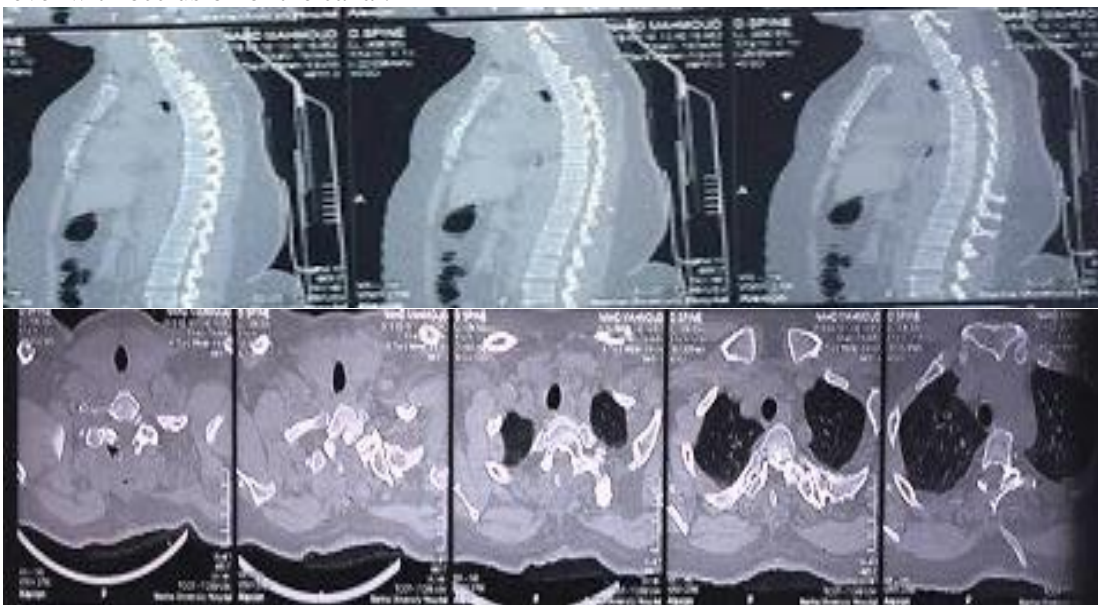
**Operative details:** A high-speed drill, osteotomes, curettes, and kerisson ronguers were used in a thorough procedure to do the posterior decompression.



**Fig (1):** Midsagittal and axial computed tomographic imaging scans of D1-2 & D2-3 herniated discs. Compression was lateral on RT side in D1-2 and central in D2-3 with associated thickening of lamina.



**Fig 2.** Midsagittal CT image and associated axial MRI images demonstrating a central calcified disc at T7-8 spinal level with occlusion of the canal.



**(Fig 3).** Midsagittal and associated axial computed tomographic images demonstrating post-operative posterior decompression at D1-2& D2-3.

Spinal stenosis patients are categorized based on the severity of their condition and how long they have been experiencing symptoms. In terms of spinal stenosis severity, four patients had a degree of stenosis more than 40%, whereas three patients' stenosis was less than 40%.

**In 4 patients with a degree of spinal stenosis > 40%: preoperatively**, according to diagnostic criteria, one patient had ASIA-B, while three had ASIA-C. Two patients qualified for mFAC's category II, while two patients qualified for category III based on their clinical presentation. Three patients showed a post-operative improvement in their ASIA grade, while one patient's ASIA grade remained the same. Also, the mFAC table showed that three patients had mFAC stage improvement of 75%, while one patient showed no change (25%) (**Table 3**).

**Table (3):** Patients with degree of spinal stenosis > 40%

Age & Sex	Level of stenosis	Degree of stenosis	Pre - op ASIA	Post - op ASIA		Pre - op mFAC	Post - op mFAC after 6 <sup>th</sup> months
				1 <sup>ST</sup> week	6 <sup>th</sup> month		
Female ,47y	D1-2	60%	C	C	D	II	IV
	D2-3	75%					
Male , 53y	D7-8	50%	B	B	C	II	III
Female, 59y	D11-12	60%	C	B	C	III	III
Female, 62y	D9-10	55%	C	C	D	III	V

**In 5 patients with a degree of spinal stenosis < 40%: preoperatively**, clinical criteria for ASIA-C were satisfied by 2 patients, ASIA-D by 3 patients, ASIA-III by 2 patients, ASIA-V by 2 patients, and ASIA-VI by 1 patient. One instance of ASIA grade D improvement and four cases of ASIA grade E improvement were observed postoperatively. Table (4) showed that three patients had improvement with mFAC stage VII, one patient with stage VI, and one patient with stage V.

**Table (4):** Patients with a degree of spinal stenosis < 40%

Age & Sex	Level of stenosis	Degree of stenosis	Pre - op ASIA	Post - op ASIA		Pre - op mFAC	Post - op mFAC after 6 <sup>th</sup> months
				1 <sup>ST</sup> week	6 <sup>th</sup> month		
Female , 59y	D11-12	40%	C	C	D	III	V
Male, 63y	D9-10	30%	D	E	E	V	VII
Male, 67y	D11-12	35%	C	D	E	III	VI
Male ,54y	D 7-8	32%	D	E	E	V	VII
Female , 58y	D 8-9	25%	D	E	E	VI	VII

**In 5 patients with a duration of clinical presentation > 1 year: pre operatively**, the clinical criteria for ASIA-C were satisfied in three individuals, while those for ASIA-D were met in two patients. For mFAC, 1 patient was in clinical category II, 2 patients were in clinical category III, 1 patient was in clinical category V, and 1 patient was in clinical category VI. Four patients showed post-operative improvement to the ASIA grades of D and E (80%), whereas one patient remained at grade C (20%). Four patients showed improvement in mFAC stages III, V, and VII (80%), whereas one patient remained unchanged in stage II (20%) (**Table 5**).

**Table (5):** Patients with a duration of clinical presentation > 1 year

Age & sex	Level of stenosis	Duration of symptoms	Pre- op ASIA	Post- op ASIA		Pre- op mFAC	Post- op mFAC after 6 <sup>th</sup> months
				1 <sup>st</sup> week	6 <sup>th</sup> month		
female, 47y	D1-2 & D2-3	24 months	C	C	D	II	III
Female, 59y	D11-12	33 months	C	B	C	III	III
Female, 62y	D9-10	13 months	C	C	D	III	V
Male ,54y	D 7-8	16 months	D	E	E	V	VII
Female, 58y	D 8-9	17 months	D	E	E	VI	VII

**In 4 patients with a duration of clinical presentation < 1 year:**

**preoperatively**, One patient fulfilled the clinical requirements for ASIA-B, one patient fulfilled the clinical requirements for ASIA-C, and two patients fulfilled the clinical requirements for ASIA-D. Furthermore, according to mFAC, one patient fulfilled the clinical requirements for category II, one patient fulfilled the clinical requirements for category III, one patient fulfilled the clinical requirements for category V, and one patient fulfilled the clinical requirements for category VI. Postoperatively, four patients had a 100% improvement rate, and the mFAC table showed that the same number of patients had a 100% improvement rate (**Table 6**).

**Table (6):** Patients with duration of clinical presentation < 1 year

Age & sex	Level of stenosis	Duration of symptoms	Pre – op ASIA	Post – op ASIA		Pre- op mFAC	Post- op mFAC after 6 <sup>th</sup> months
				1 <sup>st</sup> week	6 <sup>th</sup> month		
Male , 53y	D7-8	8 months	B	B	C	II	IV
Female ,59y	D11-12	5 months	C	C	D	III	V
Male , 63y	D9-10	2 months	D	E	E	VI	VII
Male ,67y	D11-12	7 months	D	D	E	V	VII

**Complications & mortality**

The patient's dura was torn during the operation. Another patient developed postoperative ileus, and a third developed a wound infection after surgery due to poorly managed diabetes. The wound closed without discharge after 3 weeks of parenteral antibiotic treatment, and the erythrocyte sedimentation rate (ESR) and C reactive protein (CRP) parameters also improved. No perioperative deaths were discovered during our investigation.

**DISCUSSION**

If the herniated disc in the thoracic spine is big and calcified, surgical intervention may be difficult. Thoracic disc herniation is rather prevalent between the ages of 30 and 60, and its diagnosis has increased as a consequence of developments in clinical and radiographic techniques. Acute myelopathy is an uncommon clinical manifestation of HTD, as found in studies of the disease's natural history, during which the tumor may grow yet be undetected by the patient (11,12).

Multiple particular characteristics render the thoracic spine and spinal cord vulnerable to anterior compression. The kyphosis of the thoracic spine is within healthy ranges, and the spinal cord is in close proximity to the back half of the vertebral body. Tethering of the thoracic spinal nerve roots by the dentate ligaments also restricts thoracic spinal cord movement and hence the thoracic spinal cord's capacity to escape anterior compression (13, 14, 15). Another reason why the thoracic spinal cord has less room to move than the cervical or lumbar spinal cord is the greater ratio of spinal cord diameter to canal diameter in the thoracic spine compared to the cervical and lumbar spines. Finally, the anatomical "watershed zone" makes the thoracic spinal cord vulnerable to vascular ischemia damage (16, 17, 18, 19).

Disc herniation in the thoracic area is more likely to occur in the central region, and calcification is more prevalent than in the cervical or lumbar regions. They may get embedded in the dura and eventually wear it away (19, 20).

Clinical signs originate from spinal cord dysfunction caused by local vascular compression. Interestingly, Fujimaki *et al.* (21) found in their animal investigation that the onset of spinal ischemia requires the blockage of at least five consecutive bilateral segmental arteries. The etiology of symptomatic

thoracic disc herniation, as well as the therapeutic options available, depends on these unique anatomical aspects of the thoracic spine and spinal cord. For the transthoracic technique, several publications suggest utilizing preoperative magnetic resonance angiography (MRA) to pinpoint the artery of Adamkiewicz (22).

If functional complaints persist after conservative therapy, if neurological symptoms arise or increase, and if an MRI reveals myelopathy (characterized by hypointense T1 signal and intramedullary hyperintense T2 signal), then surgical intervention may be warranted (23).

The authors Oitment *et al.* (24) conducted a series to evaluate the efficacy of posterior laminectomy alone for the treatment of calcified thoracic discs in the elderly. Out of the eight instances examined, five showed improvement after receiving treatment consisting of posterior laminectomy without discectomy.

Surgeons should be aware of the posterior approach since Liu *et al.* (18) studied it in a series and found it to be a highly safe and successful strategy for managing calcified thoracolumbar disc herniation. Patients were included in the research and underwent posterior midline approaches, posterior decompression, discectomy, and posterior fusion, with improvement in 21 instances and preservation of spinal stability.

Thoracotomy and a hemivertebrectomy have been previously reported by Debnath *et al.* (8) to provide enhanced exposure and direct visualization for herniated thoracic disc excision. This method allows the surgeon to treat two successive levels of disc herniation with a single level of vertebrectomy, and it provides a better normal plane extending cephalic and caudal to the herniated disc. When dealing with a massive herniated disc in the thoracic spine, Hott *et al.* (15) advised doing a two-level corpectomy and instrumented fusion through open thoracotomy. For asked what factors are most important when deciding on the optimal surgical strategy to reduce morbidity, they cited the disc's size and placement. To remove these calcified discs, the reported techniques seem somewhat extensive.

Research comparing the front and posterior thoracotomy approaches was conducted by Hrabálek (25). Instances with both calcified disc herniation (11 cases) and soft disc herniation (17 cases) were considered in this research. Improvements were seen more often in patients who had anterior thoracotomy. As a result, the authors concluded that anterior

thoracotomy is preferable when dealing with such situations.

More recently, **Cho et al.** (26) have employed a robotic holder and 3-D guidance to perform a minimally invasive oblique paraspinous approach. They were cautious against using this course of action, however, if the herniation is sequestered, calcified, or otherwise hard. When it comes to thoracic paracentral soft discs, the posterior transdural approach is another surgical option for some individuals. Due to the potential requirement for severe manipulation, this method is not advised for cases with large calcified thoracic disc herniation.

## CONCLUSION

Our research found that the degree of spinal stenosis (40%) and the length of time between the onset of symptoms and surgery (1 year) were the two most important factors in determining post-operative prognosis. Complications from direct decompression of the disc space, such as cardiopulmonary insufficiency, may be too great for elderly patients to warrant the procedure. The vast majority of patients who had non-instrumented laminectomy showed an improvement of at least one point on the ASIA or mFAC scales.

- **Conflict of interest:** The authors declared no conflict of interest.
- **Sources of funding:** This research did not receive any specific grant from funding agencies in the public, commercial, or not-for-profit sectors.
- **Author contribution:** Authors contributed equally in the study.

## List of abbreviations:

- ASIA: American Spinal Injury Association Impairment Scale.
- HDS: herniated thoracic discs.
- CTD: calcified thoracic discs.
- mFAC: modified Functional Ambulatory Category.
- MRA: magnetic resonance angiography.
- TDH: thoracic disc herniation.

## REFERENCES

1. **American Spinal Injury Association (2015):** Worksheet International standards for neurological classification of spinal cord injury (ISNCSCI); revised version November 2015. Available from: <http://asia-spinalinjury.org/information/downloads/>. Accessed March 2018.
2. **Takagi H, Ota H, Natsuaki Y et al. (2015):** Identifying the Adamkiewicz artery using 3-T time-resolved magnetic resonance angiography: its role in addition to multidetector computed tomography angiography. *Jpn J Radiol.*, 33: 749–56.
3. **Carr D, Volkov A, Rhoiney D et al. (2017):** Management of thoracic disc herniations via posterior unilateral modified transfacet pedicle-sparing decompression with segmental instrumentation and interbody fusion. *Global Spine J.*, 7: 506-513.
4. **Court C, Mansour E, Bouthors C (2018):** Thoracic disc herniation: Surgical treatment. *Orthopaedic and Traumatology Surgical Research*, 104: S31-S40.
5. **Deviren V, Kuelling F, Poulter G et al. (2011):** Minimal invasive anterolateral transthoracic transpleural approach: a novel technique for thoracic disc herniation. A review of the literature, description of a new surgical technique, and experience with first 12 consecutive patients. *J Spinal Disord Tech.*, 24 (5): E40–E48.
6. **Uribe J, Smith W, Pimenta L et al. (2012):** Minimally invasive lateral approach for symptomatic thoracic disc herniation: initial multicenter clinical experience. *J Neurosurg Spine*, 16: 264–279.
7. **Quint U, Bordon G, Rosenthal D et al. (2012):** Thoracoscopic treatment for single level symptomatic thoracic disc herniation: a prospective followed cohort study in a group of 167 consecutive cases. *Eur Spine J.*, 21: 637–45.
8. **Debnath U, McConnell J, Sengupta D et al. (2003):** Results of hemivertebrectomy and fusion for symptomatic thoracic disc herniation. *Eur Spine J.*, 12 (3): 292–299.
9. **Brauge D, Madkouri R, Reina V et al. (2017):** Is there a place for the posterior approach in cases of acute myelopathy on thoracic disc hernia? *World Neurosurg.*, 107: 744-749.
10. **Quraishi N, Khurana A, Tsegaye M et al. (2014):** Calcified giant thoracic disc herniations: Considerations and treatment strategies. *Eur Spine J.*, 23 (1): S76–S83.
11. **Guest J, Griesdale D, Marotta T (2000):** Thoracic disc herniation presenting with transient anterior spinal artery syndrome. A case report. *Interv Neuroradiol.*, 6: 327–31.
12. **Hammett T, Boreham B, Quraishi N et al. (2013):** Intraoperative spinal cord monitoring during the surgical correction of scoliosis due to cerebral palsy and other neuromuscular disorders. *Eur Spine J.*, 22 (1): S38–S41.
13. **Harshavardhana N, Panvica T, Pinto M et al. (2017):** Spontaneous Regression of a Large Symptomatic Calcified Central Thoracic Disc Herniation: A Case Report with a Review of the Literature. *J Head Neck Spine Surg.*, 1: 555-565.
14. **Ho C, Chang S, Fulkerson D et al. (2012):** Children presenting with calcified disc herniation: a self-limiting process. *J Radiol Case Rep.*, 6: 9-11.
15. **Hott J, Feiz I, Kenny K et al. (2005):** Surgical management of giant herniated thoracic discs: analysis of 20 cases. *J Neurosurg Spine*, 3: 191–197.
16. **Khurana A, Brousil J, Russo A et al. (2013):** Intracranial hypotension with a sixth cranial nerve palsy subsequent to massive thoracic CSF hygroma: a rare complication of thoracic disc excision. *Eur Spine J.*, 22 (9): 2047–2054.
17. **Kim Y, Bridwell K, Lenke L et al. (2006):** Sagittal thoracic decompensation following long adult lumbar spinal instrumentation and fusion to L5 or S1: causes, prevalence, and risk factor analysis. *Spine*, 31: 2359–66.
18. **Liu N, Chen Z, Qi Q et al. (2014):** Circumspinal Decompression and Fusion through a Posterior Midline Incision to Treat Central Calcified Thoracolumbar Disc

- Herniation: A Minimal 2-year Follow-Up Study with Reconstruction CT. *Eur Spine J.*, 23 (2): 373-381.
19. **Sengupta S (2015):** Post-operative pulmonary complications after thoracotomy. *Indian J Anesth.*, 59: 618-626.
  20. **Fujimaki Y, Kawahara N, Tomita K et al. (2006):** How many ligations of bilateral segmental arteries cause ischemic spinal cord dysfunction? An experimental study using a dog model. *Spine*, 31: E781–E789.
  21. **Russo A, Balamurali G, Nowicki R et al. (2012):** Anterior thoracic foraminotomy through mini-thoracotomy for the treatment of giant thoracic disc herniations. *Eur Spine J.*, 21 (2): S212–S220.
  22. **Sari H, Misirlioglu T, Palamar D (2016):** Regression of a symptomatic thoracic disc herniation with a calcified intervertebral disc component. *Acta Orthop Traumatol Turc.*, 50: 698–701.
  23. **Oitment C, Kwok D, Steyn C (2019):** Calcified Thoracic Disc Herniations in the Elderly: Revisiting the Laminectomy for Single Level Disease. *Global Spine Journal*, 9 (5): 527-531.
  24. **Bransford R, Zhang F, Bellabarba C et al. (2010):** Early experience treating thoracic disc herniations using a modified transfacet pedicle-sparing decompression and fusion. *J Neurosurg Spine*, 12: 221–231.
  25. **Hrabálek L, Kalita O, Langová K (2010):** Surgical Treatment of Thoracic Disc Herniation. *Acta Chir Orthop Traumatol Cech.*, 77 (4): 312-19.
  26. **Cho J, Lee S, Jang S et al. (2012):** Oblique paraspinous approach for thoracic disc herniations using tubular retractor with robotic holder: a technical note. *Eur Spine J.*, 21 (12): 2620–2625.