

***Artemisia annua* Has Anti-Psoriatic Effects Comparable to Those of Clobetasol in Imiquimod-Induced Animal Model of Psoriasis**

Noor M. Badea Abdulrahman AL-Badri ¹, Mohammed Abdul-Hassan Jabarah AL-Zobaigy ^{*1}

¹ Department of Pharmacology/ College of Medicine/ University of Baghdad- Iraq.

***Corresponding author:** Mohammed Abdul-Hassan Jabarah AL-Zobaigy, **Mobile:** 009647705982654;

Email: mohammed.a@comed.uobaghdad.edu.iq

ABSTRACT

Introduction: Psoriasis is a complex, common, chronic, non-contagious. The etiology of psoriasis remains poorly understood, but it is thought to be a complex of genetics, skin disruption, environmental, and immune dysfunction.

Methods: This study extended from December 2020 to July 2021. Plant extraction was done at Baghdad Collage of Pharmacy (a private College) while animal experiments were done at College of Pharmacy, Baghdad University. The study involved 60 apparently healthy BALB/c male mice, which were divided into 6 groups where each group contained ten animals. **Results:** Psoriasis was induced on back skin of mice by the application of imiquimod cream, revealing significant histological and morphological changes in the skin in addition to the elevated levels of skin homogenate TNF- α , IL-17, IL-23 and VEGF, and elevated levels of circulated TNF- α , IL-17, and IL-23. Additionally, there was an increase in spleen index. The current study showed that using *Artemisia annua* extract ointment as prophylactic resulted in lower levels of inflammation, spleen index, skin homogenate TNF- α , IL- 17, IL- 23 and VEGF as well as lower levels of circulating TNF- α , IL- 17, and IL- 23.

Conclusion: Both *Artemisia annua* extract ointment and Clobetasol showed an improvement in induced psoriasis, by decreasing the histological changes in skin, lowering cytokines level and in decreasing spleen index.

Keywords: *Artemisia annua*, Ethanolic extract, Imiquimod, Interleukins, Psoriasis.

INTRODUCTION

Psoriasis is a complex, common, chronic, noncontagious, recurrent, multisystem, immune-mediated inflammatory disease of skin ⁽¹⁻⁵⁾. On the other hand, the histopathological findings in psoriasis are generally characterized by three features; epidermal hyperplasia, increase vascularity in the dermis and infiltration of inflammatory leucocytes ⁽⁶⁻⁸⁾. Individuals with psoriasis have a high prevalence of developing several distinct comorbidities such as metabolic syndrome ⁽⁹⁾, insulin resistance ⁽¹⁰⁾ and/or Hypertension ⁽¹¹⁾.

Traditional pharmacological treatment of psoriasis includes topical agents such as retinoids, vitamin D, topical corticosteroids, topical keratolytics and topical calcineurin inhibitors ^(12,13). Moreover, systemic agents can also be useful in treatment of psoriasis, these may include phosphodiesterase 4 inhibitors, cyclosporine A and methotrexate ^(12,14,15).

Nonetheless, modern pharmacological treatments (such as phototherapy and biologics) have been successfully employed in treatment of psoriasis. These include, but not limited to, ultraviolet B ⁽¹⁶⁾, Psoralin ultraviolet A (PUVA) ⁽¹⁷⁾, TNF- α inhibitors ⁽¹⁸⁾, IL-17 inhibitors ⁽¹³⁾ and IL - 23 inhibitors ⁽¹⁹⁾. Interestingly, complementary and alternative medicines are nowadays used to supplement or replace traditional treatment and they include dietary supplements, traditional Chinese medicines, herbal/botanical therapy, mind body intervention and climatotherapy ⁽²⁰⁾. Throughout the history, three herbal medicines were commonly used for treatment of psoriasis; Aloe Vera ⁽²¹⁾, Mahonia Aquifolium ⁽²²⁾ and Indigo Naturalis ⁽²³⁾.

Among medicinal plants, *Artemisia annua* is considered as one of the most common plants that is prescribed in traditional Chinese medicine for more than two thousand years. Also, studies have been done to evaluate the potential effects ⁽²⁴⁾ of the plant to cure variety of ailments. These include antihypertensive, antimicrobial, anti-inflammatory, antioxidant, immunosuppressive and antiparasitic effects. Despite the broad spectrum of pharmacological therapies available for treatment of psoriasis, they are associated with a wide range of adverse effects. Taken together, current study aimed to evaluate the possible prophylactic and therapeutic effects of *Artemisia annua* extract on imiquimod-induced psoriasis in mice.

METHODS

This study extended from December 2020 to July 2021. Plant extraction was done at Baghdad Collage of Pharmacy (a private College). The plant *Artemisia annua* was purchased from the local market in Baghdad and authenticated at Al-Razi center, which is an authorized center for alternative medicine in Baghdad, Iraq. after extraction of the leaves, numerous qualitative phytochemical screening studies were conducted to determine the chemical composition of the extract. Then, the extract was formulated into an ointment by trituration method. Moreover, the study involved 60 apparently healthy BALB /c male mice, which were divided into six groups (normal control, prophylaxis, induction, treatment with Vaseline, treatment with clobetasol and treatment with *Artemisia annua* extraction) where each group

contained ten animals. To induce psoriasis in the mice, commercially available Imiquimod 5% cream (Aldara; 3MPharmaceuticals) was topically applied on the mice's shaved dorsal skin for nine consecutive days, a daily topical dosage of 62.5 mg of the medication was applied, equivalent to a daily dose of (3.125 mg) of the active component [25]. After completing the experiments, blood samples were collected from each animal to measure serum levels of TNF- α , IL-17, IL-23 and VEGF. Moreover, spleens were isolated and spleen index was calculated for each animal. Assessment of TNF- α , IL- 17, IL- 23 and VEGF was done by Enzyme-Linked Immunosorbent Assay technique.

Ethical Approval:

Ethical Approval was obtained from the Scientific Research Ethics Committees at Department of Pharmacology/ College of Medicine and College of Pharmacy, University of Baghdad, Iraq. This work has been carried out in accordance with The Code of Ethics of the World Medical Association (Declaration of Helsinki) for studies involving humans.

Statistical analysis

Quantitative data were represented as mean \pm SD, minimum and maximum. Normality distribution was tested using Shapiro - Wilk test and all markers were found to be normally distributed In this study, statistical significance was determined by a P-value of less than 0.05.

RESULTS

Phytochemical screening of *Artemisia annua* extract:

The results of current study showed that after extraction of the leaves, a dark green residue was obtained. In addition, after carrying out numerous qualitative phytochemical screening studies to determine the chemical composition of the extract, the results revealed the existence of a number of phytochemical ingredients in the obtained extract Table (1).

Table (1): Qualitative analysis of *Artemisia annua* extract

Phytochemical constituent	Test result
Alkaloids	+ve*
Saponins	-ve**
Tannins	-ve
Flavonoids	+ve
Coumarines	+ve
Glycosides	+ve
Terpenoids	+ve

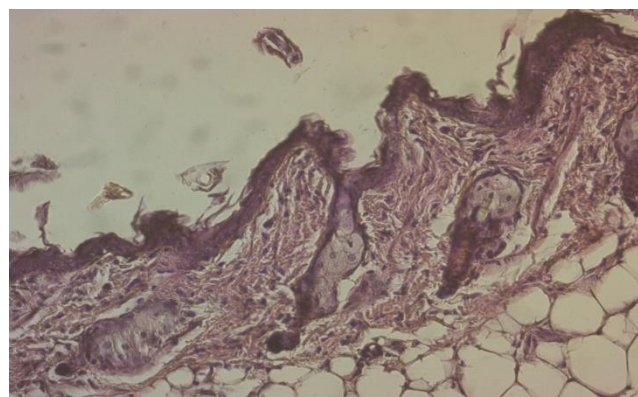
*/**: Represents the presence/or absence of phytoconstituents, respectively.

Formulation of *Artemisia annua* extract ointment: The result of the trituration method with vaseline at room

temperature was 5% (w/w) of *Artemisia annua* extraction ointment.

Validity of the animal model:

The normal histological features of skin from a control (not treated) were shown in Figure (1). On the other hand, data from current study reported that the skin from mice treated with imiquimod (5% cream for nine days) showed histopathological features Figure (2) different from those seen in Figure (1), however the former were quietly similar to those reported in human psoriatic skin (Figure 3). These findings support the face and construct validities of the model. Moreover, regarding predictive validity of the model, data from current study showed that the induced psoriatic lesions in the skin of



experimental mice showed a response to clobetasol similar to that expected in human skin (Figure 4).

Figure (1): Section of normal skin from control mouse (H&E stain 20X). The section showed normal skin tissue composed of the upper layer (epidermis) and deep to it is the dermis containing connective tissue, sebaceous glands, and hair follicles, deep to it is the subcutaneous fat.

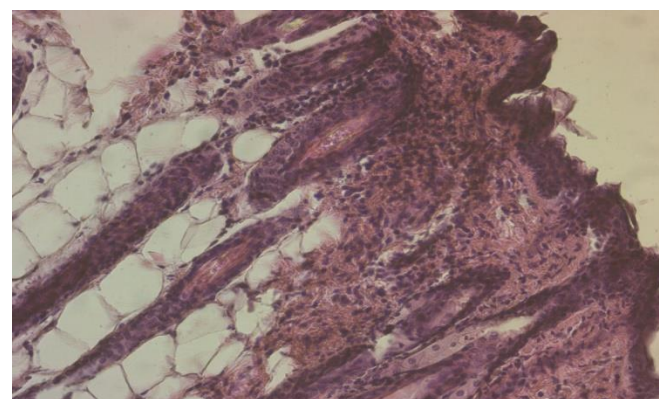


Figure (2): Section of psoriatic skin from mouse (H & E stain 20X). Section of psoriatic skin from mouse induced with topical imiquimod (5% cream for nine days). The section showed severe acanthosis, elongation of rete ridges, inflammatory cells infiltrate in the dermis, with marked hyperkeratosis and parakeratosis.

Skin histopathological changes in group V: treatment with clobetasol.

This section showed thinning of the skin predominantly the epidermis, no hyperkeratosis, no inflammatory cells, and no elongation of rete ridges.

Effects of *Artemisia annua* extract on serum levels of IL-17, IL-23, TNF and VEGF

Results of serum levels of IL-17, IL-23 and TNF- α and VEGF from this study were presented in table (2) and Figures (5 - 8).

They showed that in the prophylactic group (group II), there was significant ($p=0.005$) increase in the levels of IL-17, IL-23, TNF- α in comparison with the control group (group I).

In addition, serum levels of IL-17, IL-23, TNF- α in the prophylactic group were also significantly ($p = 0.005$) lower than those in induction group (group III).

Treatment with *Artemisia annua* extract (group VI) resulted in a significant ($p =0.005$) decrease in the levels of IL-17, IL-23, TNF- α in comparison with those treated with vaseline only (group IV).

However, serum levels of VEGF showed no significant differences among all groups ($p>0.05$).

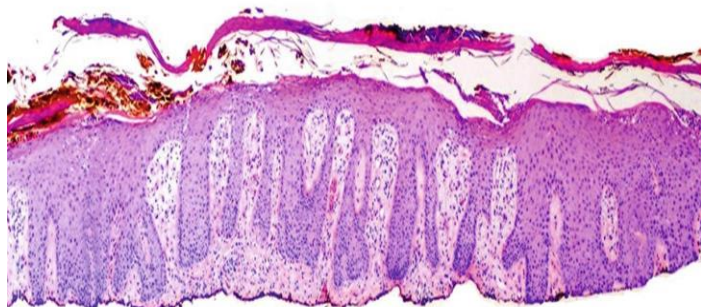

Figure (3): Section of human skin with psoriasis. The section shows hyperkeratosis, parakeratosis, and acanthosis of the epidermis [26].

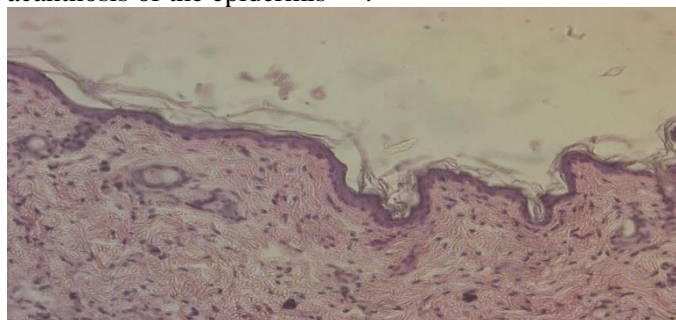


Figure (4): Section of mice skin psoriasis treated with Clobetasol (H&E stain 20X).

Table (2): Comparison of IL-17, IL-23, TNF- α , and VEGF in the different study groups

Variable			IL-17 pg/ml	IL-23 pg/ml	TNF pg/ml	VEGF pg/ml
	Control (Group 1)	Mean	269.60	192.10	29.01	163.44
		SD	11.89	13.95	0.89	1.81
G II n=10	Prophylaxis with A. A. extract	Mean	402.31	393.40	35.24	164.22
		SD	14.51	15.65	0.93	1.67
G III n=10	Induction	Mean	747.70	605.50	41.32	162.85
		SD	30.98	53.43	6.00	2.79
G IV n=10	Induction + Vaseline	Mean	676.15	511.30	38.73	163.83
		SD	22.67	19.49	0.91	1.79
G V n=10	Induction + clobetasol	Mean	129.63	121.25	22.61	163.60
		SD	21.16	18.55	0.83	1.16
G VI n=10	Induction + A. A. extract	Mean	31 3.20	210.70	33.18	161.02
		SD	20.82	19.79	1.07	8.86

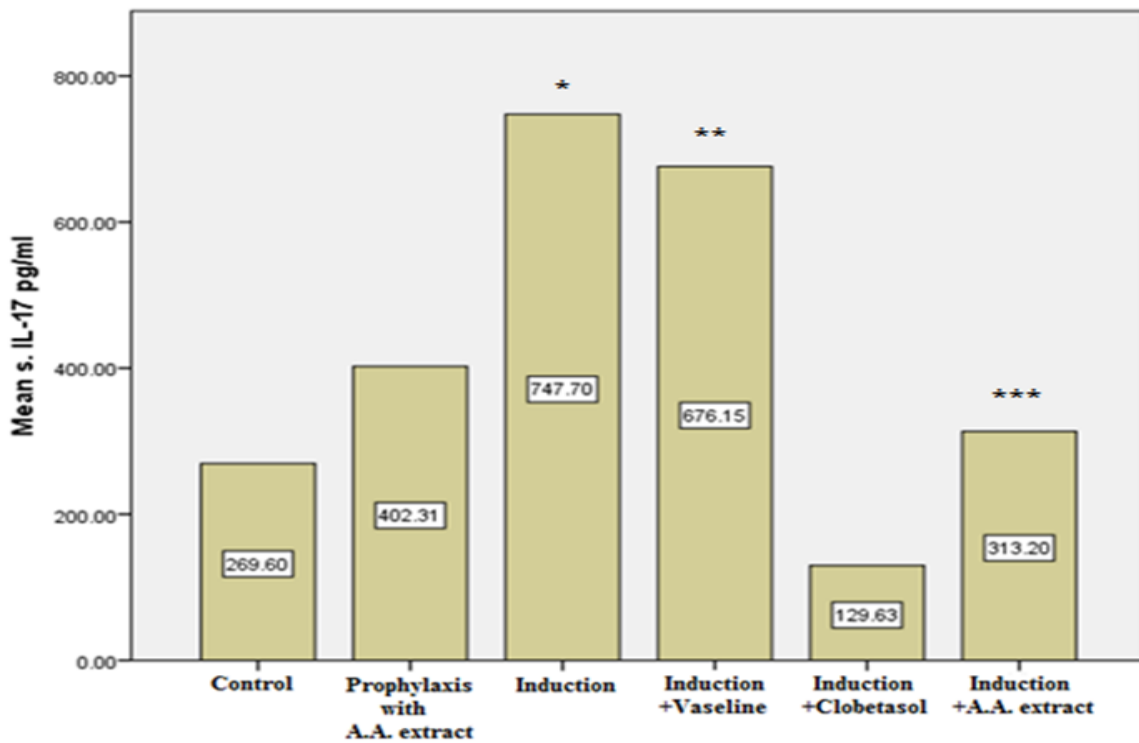


Figure (5): Comparison of IL-17 in different groups

*: Significant differences with control (G I) (P=0.005), and prophylaxis group with A.A. extract (G II) (P=0.005). **: Significant differences with induction group (G III) (P=0.005). ***: Significant differences with induction group (G III) (P=0.005), induction +Vaseline (G IV) (P=0.005), and induction + Clobetasol (G V) (P=0.005).

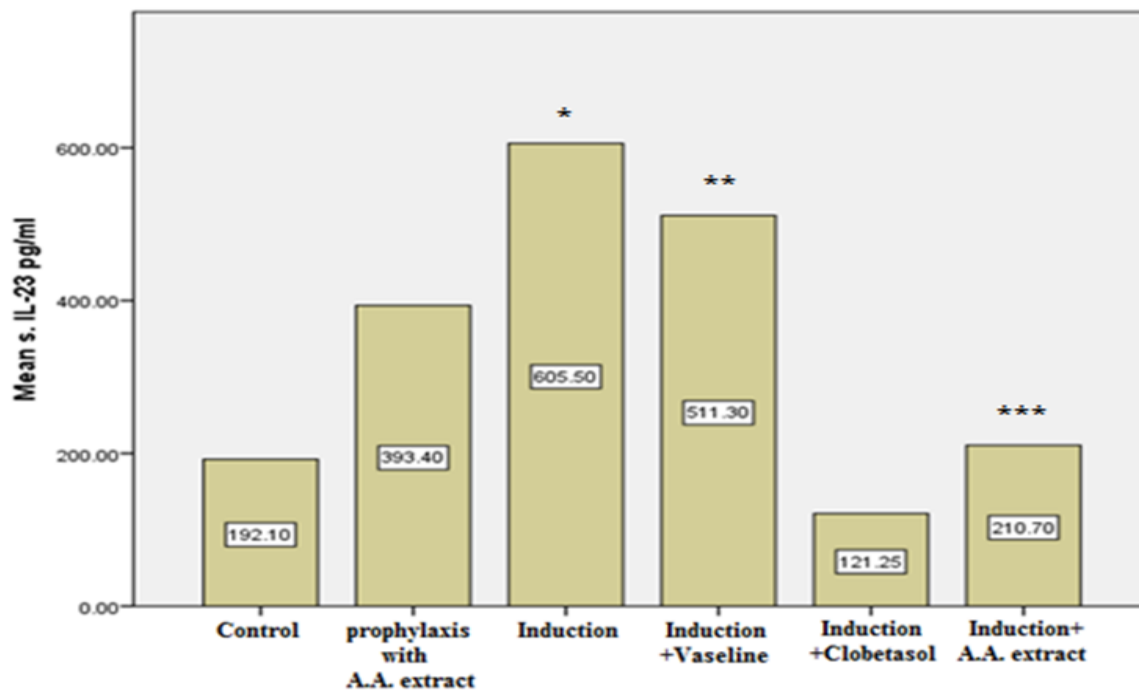


Figure (6): Comparison of IL-23 in different groups

*: Significant differences with control (G I) (P=0.005), and prophylaxis group with A.A. extract (G II) (P=0.005). **: Significant differences with induction group (G III) (P=0.005). ***: Significant differences with induction group (G III) (P=0.005), induction +Vaseline (G IV) (P=0.005), and induction + Clobetasol (G V) (P=0.005), and non-significant differences with respect to normal control (P>0.05).

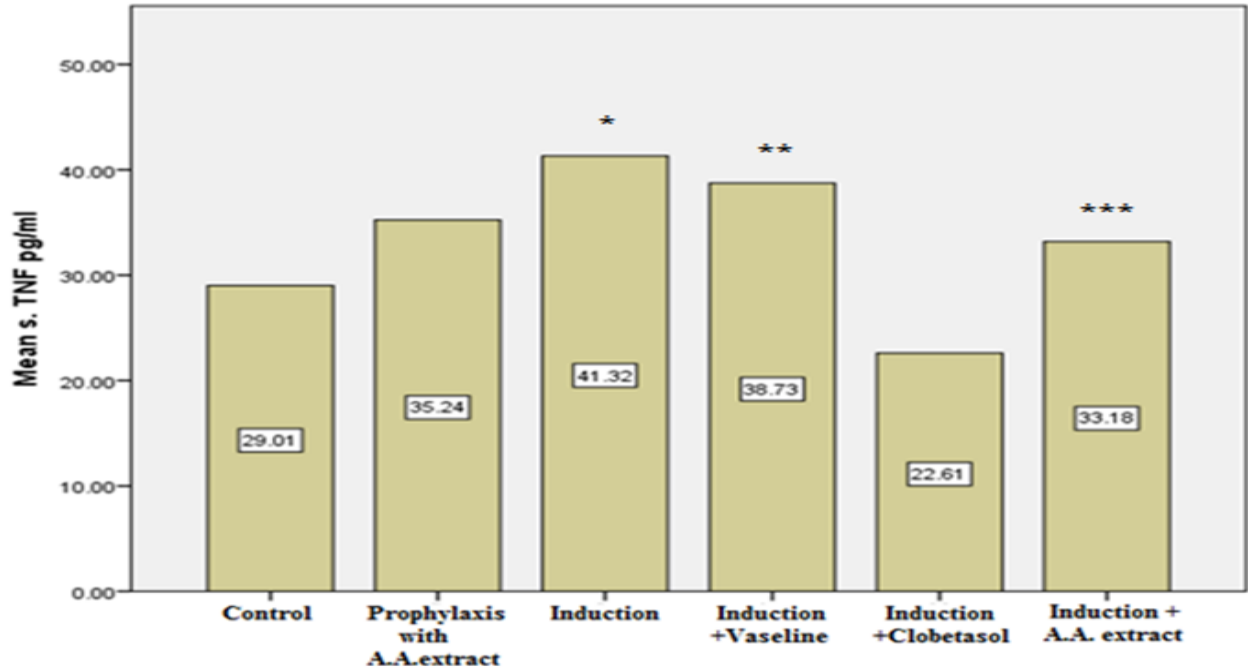


Figure (7): Comparison of TNF- α between different groups

*: Significant differences with respect to control (G I) (P=0.005), and prophylaxis group with A.A. extract (G II) (P=0.005). **: Significant differences with induction group (G III) (P=0.008). ***: Significant differences with induction group (G III) (P=0.005), induction +Vaseline (G IV) (P=0.0050, and induction +Clobetasol (G V) (P=0.005).

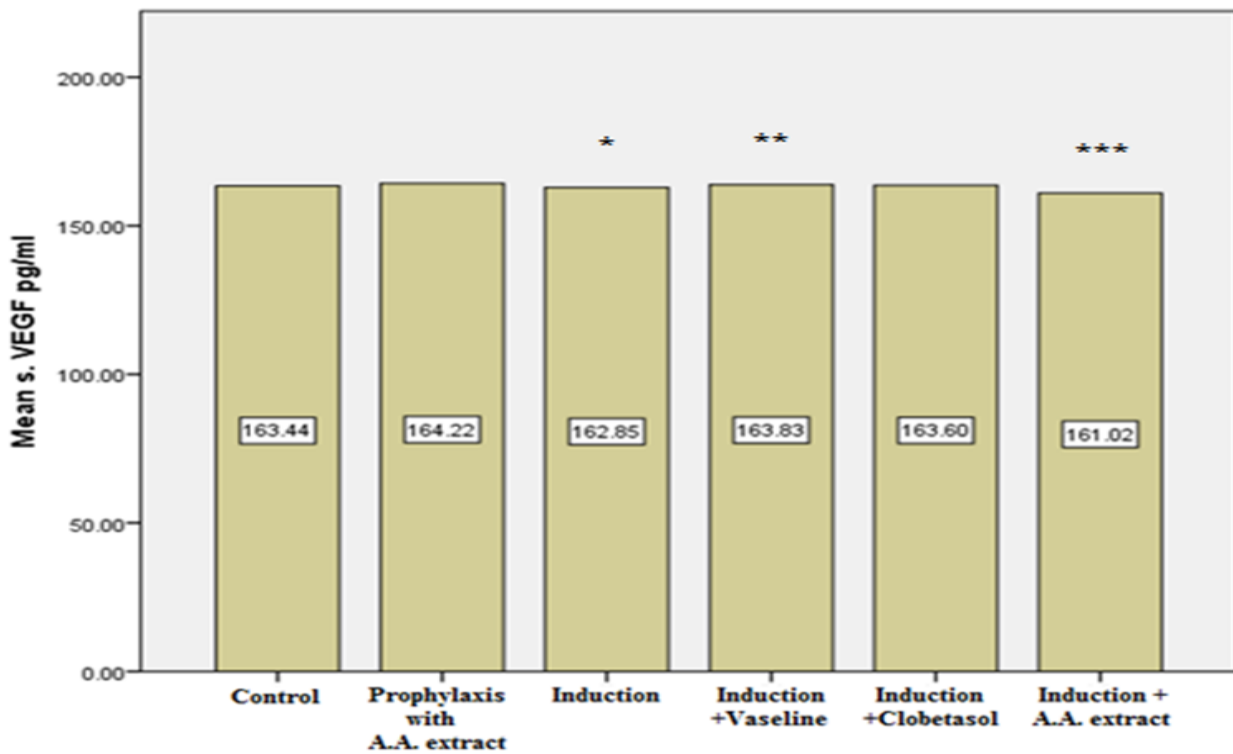


Figure (8): Comparison of VEGF in different groups

*: Non-significant differences with respect to control (G I) (P>0.05), and prophylaxis group with A.A. extract (G II) (P>0.05). **: Non-significant differences with induction group (G III) (P>0.05). ***: Non-significant differences with induction group (G III) (P>0.05), induction +Vaseline (G IV) (P>0.05), and induction +Clobetasol (G V) (P>0.05).

Effects of *Artemisia annua* extract on skin levels of IL-17, IL-23, TNF and VEGF

Results of skin homogenates levels of IL-17, IL-23 and TNF- α and VEGF from this study were presented in Table (3) and Figures (9-12). They showed that in the prophylactic group (group II) there was significant increase in the levels of IL-17, IL-23, TNF- α , and VEGF in comparison with the control group (group I). In addition, the skin homogenates levels of IL-17, IL-23, TNF- α , and VEGF in the prophylactic group were also significantly ($p=0.005$) lower than those in induction group (group III). Treatment with *Artemisia annua* extract (group VI) resulted in a significant ($p=0.005$) decrease in the levels of IL-17, IL-23, TNF- α and VEGF in comparison with those treated with vaseline only (group IV).

Table (3): Comparison of skin levels of IL-17, IL-23, TNF- α and VEGF in the different study groups

Variable			IL-17 pg/ml	IL-23 pg/ml	TNF pg/ml	VEGF pg/ml
G I n=10	Control	Mean	212.43	79.53	78.59	201.74
		SD	2.80	5.17	5.45	8.30
G II n=10	Prophylaxis with A.A. extract	Mean	228.55	227.83	171.25	303.41
		SD	9.10	9.52	8.34	10.98
G III n=10	Induction	Mean	297.13	363.09	385.55	473.28
		SD	35.67	10.55	10.58	11.24
G IV n=10	Induction +Vaseline	Mean	290.75	292.18	358.37	402.34
		SD	10.12	14.84	21.65	12.82
G V n=10	Induction +clobetasol	Mean	155.91	176.77	103.28	213.22
		SD	4.72	6.47	12.25	8.94
G VI n=10	Induction+ A.A. extract	Mean	174.29	198.30	148.65	264.74
		SD	9.49	14.41	11.03	10.88

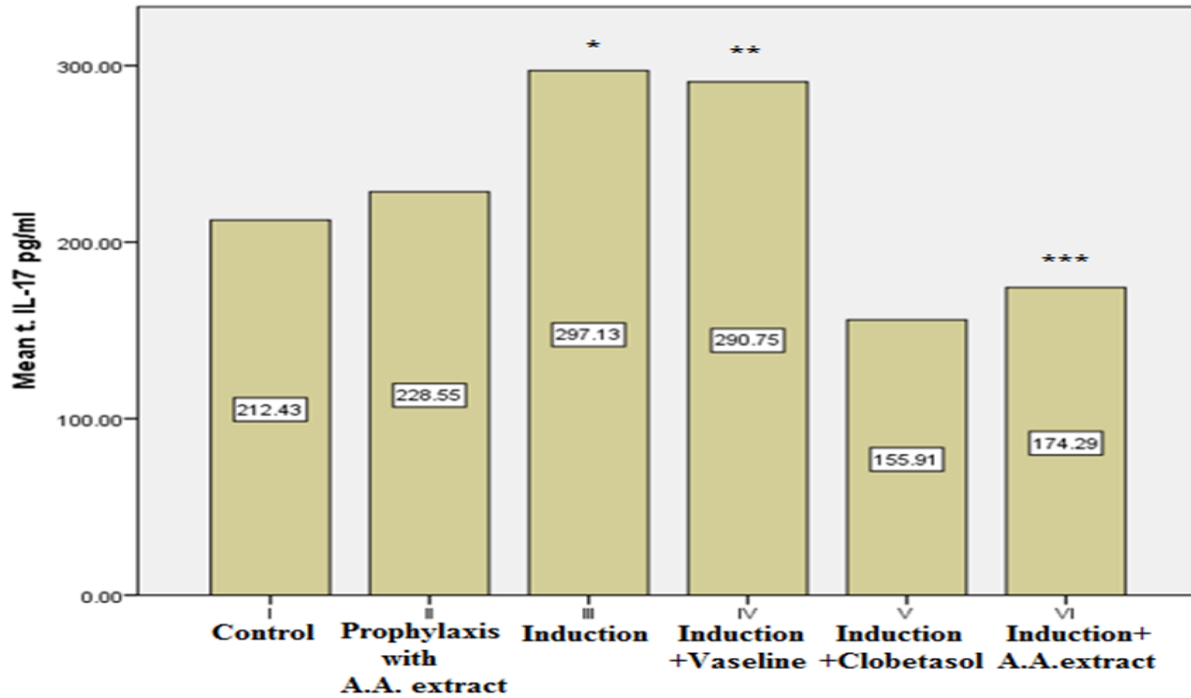


Figure (9): Comparison of skin homogenate levels of IL-17 in the different study groups

*Significant differences with control (G I) ($P=0.005$), and prophylaxis group with A.A. extract (G II) ($P=0.005$). **: Non-significant differences with induction group (G III) ($P>0.05$). ***: Significant differences with induction group (G III) ($P=0.005$), induction +Vaseline (G IV) ($P=0.005$), and induction +Clobetasol (G V) ($P=0.016$).

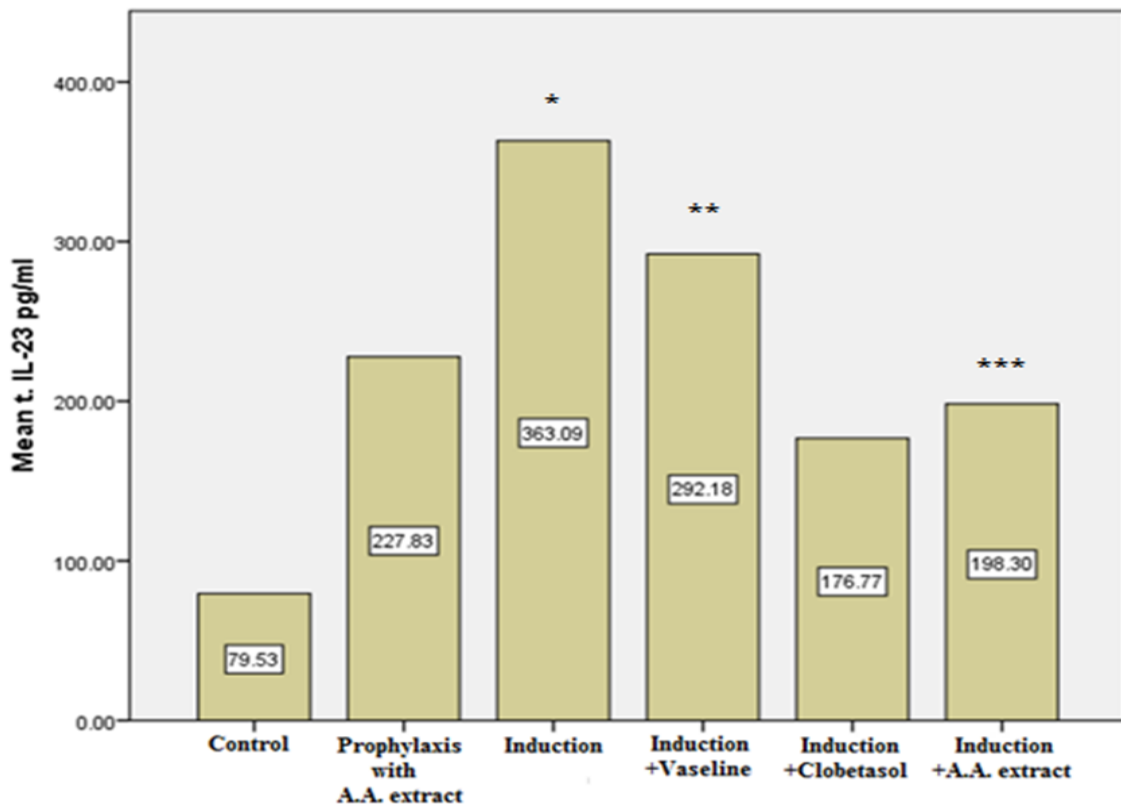


Figure (10): Comparison of skin homogenate levels of IL-23 in the different study groups

* Significant differences with control (G I) (P=0.005), and prophylaxis group with A.A. extract (G II) (P=0.005). **: Significant differences with induction group (G III) (P=0.005). ***: Significant differences with induction group (G III) (P =0.005), induction +Vaseline (G IV) (P=0.005), and induction +Clobetasol (G V) (P =0.005).

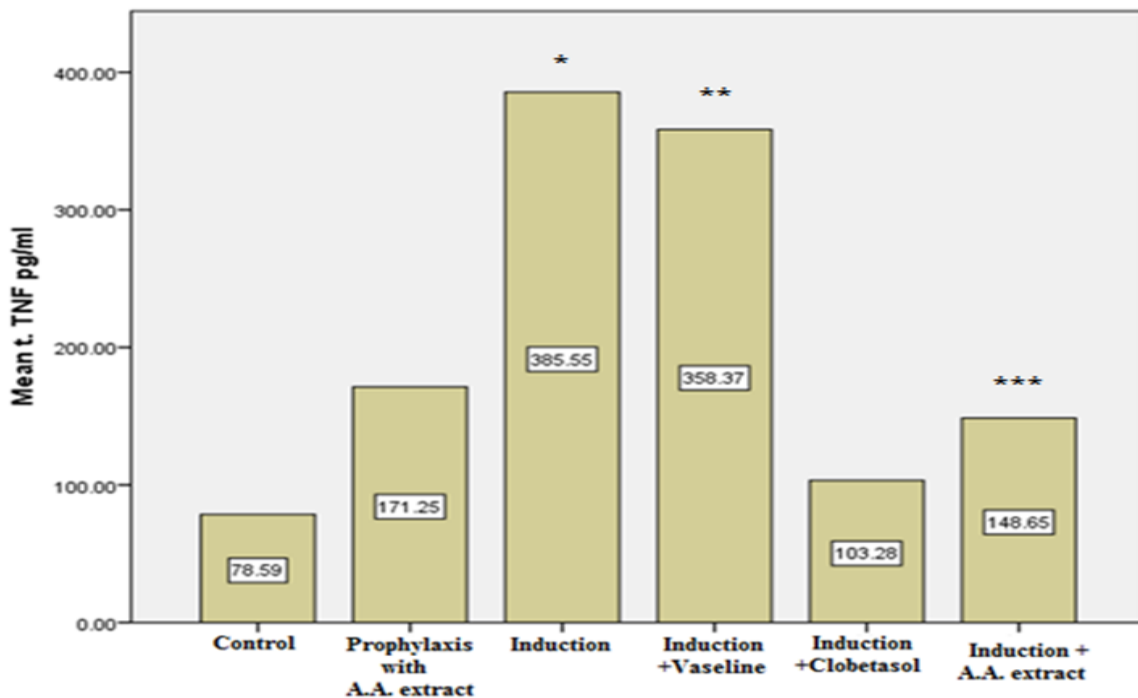


Figure (11): Comparison of skin homogenate levels of TNF- α in the different study groups.*: Significant differences with respect to control (G I) (P=0.005), and prophylaxis group with A.A. extract (G II) (P =0.005). **: Significant differences with induction group (G III) (P=0.005). ***: Significant differences with induction group (G III) (P=0.005), induction +Vaseline (G IV) (P =0.005), and induction +Clobetasol (G V) (P=0.005).

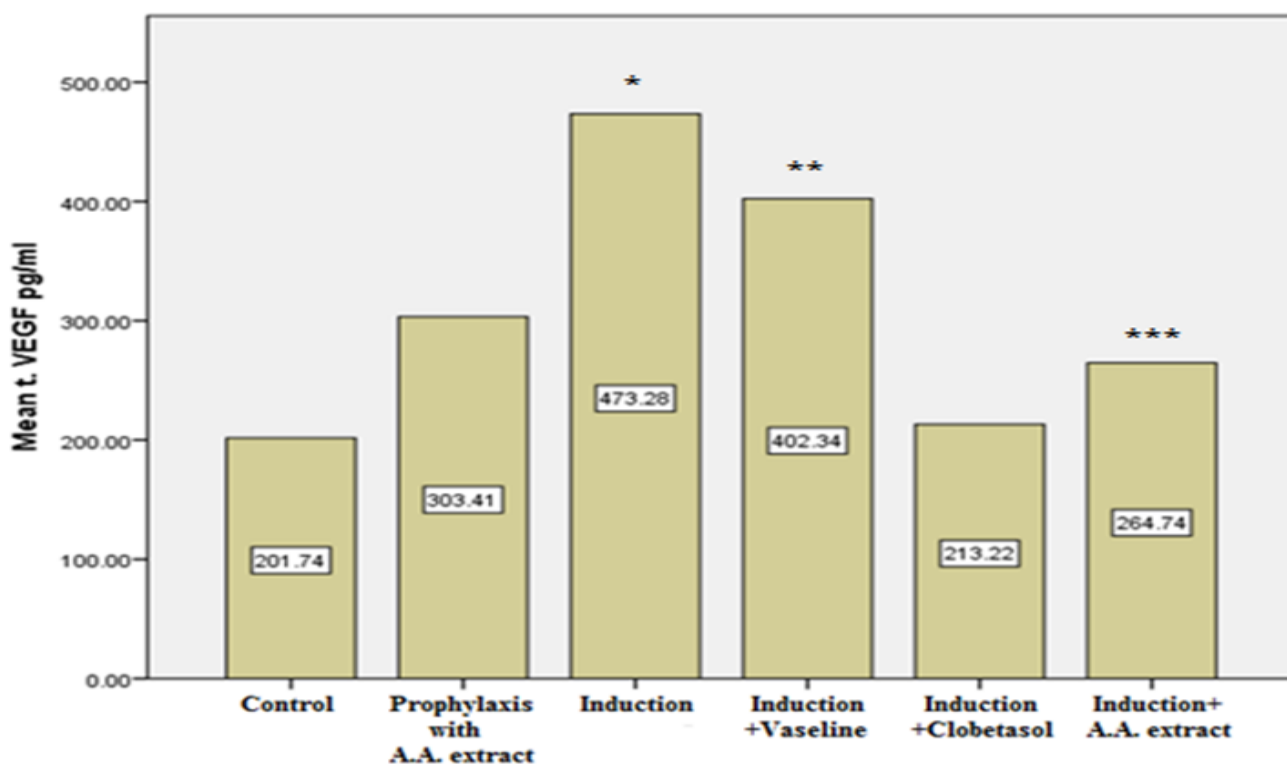


Figure (12): Comparison of skin homogenate levels of VEGF in the different study groups.

* Significant differences with control (G I) (P=0.005), and prophylaxis group with A.A. extract (G II) (P=0.005). **: Significant differences with induction group (G III) (P=0.0050). ***: Significant differences with induction group (G III) (P=0.005), induction +Vaseline (G IV) (P=0.005), and induction +Clobetasol (G V) (P=0.005).

DISCUSSION

Phytochemical screening of *Artemisia annua* extract

Tests on *Artemisia annua* extract in current study revealed the presence of alkaloids, flavonoids, coumarines, glycosides, and terpenoids. Extraction of *Artemisia annua* leaves using ethanol as solvent resulted in higher flavonoids content [27]. Furthermore, the procedure of extraction of *Artemisia annua* leaves in this study involved the use of ethyl acetate, because ethyl acetate is the best solvent used for flavonoids enrichment (28-29). In the last decades a lot of studies on medicinal plants focused on flavonoids and other phenolic compounds. Terpens have been reported to have anti-cancer and a good immune-modulatory effect (30-31). *Artemisia annua* plant includes alkaloids, coumarines, flavonoids, terpenoids, steroids and benzenoids (32).

Ointment formulation

It was believed that ointments are more effective than other topical formulation containing the same active ingredients for the treatment of various skin diseases, this may be due to the homogenous spreading along the applied areas, offering more protection against moisture loss, as well as being less irritant and more soothing than

other topical dosage form (33). Vaseline considers as the most common ointment base used because of its availability, low cost, extreme inertness and it does not cause any skin sensitization. In the recent study, the formulation of ointment of *Artemisia annua* extract was done by trituration method because of the presence of volatile substances within the extract that may be affected by applying heat.

Validity of the animal model

Daily topical application of Imiquimod 5% cream [Aldara®] on mice shaved back skin resulted in psoriasis-like dermatitis that manifested by erythema, scaling and acanthosis (34). This inflamed skin lesion resembles plaque type of human psoriasis in phenotype and histological characteristics.

In current study, H & E-stained sections showed that topical application of imiquimod cream 5% on the shaved back skin of mice (group III) resulted in visible inflammation characterized by erythema, scaling and thickening that started at day two and increased onward. The similarities of histopathological changes in the current study with histopathological changes that occur in

human psoriasis suggested the validity of the animal model in studying this disease. On the other hand, shaved back skin of mice treated with vaseline (control cream; group I), for nine days did not show any feature of inflammation.

Effects of *Artemisia annua* extract on skin levels of IL-17, IL-23, TNF and VEGF

This study showed significant increase IN levels of IL-23, IL-17, TNF- α and VEGF in tissue homogenates of inflamed skin from mice induced with imiquimod (group III) in comparison with normal controls (group I). This triggers a huge release of inflammatory factors such as INF- α , IL-6 and IL-23 leading to IL-23/IL-17 axis expression as well as an increase in the release of pro-inflammatory mediators including TNF- α .

CONCLUSION

The ethanolic extract of *Artemisia annua* showed beneficial therapeutic effects on imiquimod-induced psoriasis in skin of mice which were comparable to those induced by the standard treatment, clobetasol.

Conflict of interest: The authors declare no conflict of interest.

Sources of funding: Did not receive any specific grant for-profit sectors.

Author contribution: Authors contributed equally in the study.

REFERENCES

1. **Morais P, Oliveira M, Matos J et al. (2013):** A potential precipitating factor for Koebner phenomenon in psoriasis? *Dermatol. Online J.*, 19 (1): 18186.
2. **Puri P, Nanda S, Kathuria S et al. (2017):** Effects of air pollution on the skin: A review. *Indian J. Dermatol. Venereol. Leprol.*, 83 (2): 415–423.
3. **Zhang P, Wu M (2018):** A clinical review of phototherapy for psoriasis. *Lasers Med. Sci.*, 33: 173–180.
4. **Kamiya K, Kishimoto M, Sugai J et al. (2019):** Risk Factors for the Development of Psoriasis. *International Journal of Molecular Sciences*, 20: 4347
5. **Raho G, Koleva D, Garattini M et al. (2012):** the burden of moderate to severe psoriasis. *Pharmacoeconomics*, 30 (3): 1005-1013
6. **Wenqing L, Jiali H, Hyon K et al. (2012):** Smoking and Risk of Incident Psoriasis Among Women and Men in the United States: A Combined Analysis. *American Journal of Epidemiology*, 175 (5): 402–413
7. **Lee E, Han K, Han J et al. (2017):** Smoking and risk of psoriasis: A nationwide cohort study. *J. Am. Acad. Dermatol.*, 77 (5): 573–575.
8. **Krueger JG, Bowcock A (2005):** Psoriasis pathophysiology: current concepts of pathogenesis. *Ann Rheum Dis.*, 64 (II): ii30–36.
9. **Ryan C, Kirby B (2015):** Psoriasis is a systemic disease with multiple cardiovascular and metabolic comorbidities. *Dermatol Clin.*, 33: 41–55.
10. **Romiti R, Paschoal R, Meneghello L (2016):** Psoriasis comorbidities: complications and benefits of immunobiological treatment. *An Bras Dermatol.*, 91 (6): 781-9.
11. **Rose S, Sheth N, Baker J et al. (2013):** A comparison of vascular inflammation in psoriasis, rheumatoid arthritis and healthy subjects by FDG-PET/TC: a pilot study. *Am J Cardiovasc Dis.*, 3 (1): 273-8.
12. **Ogawa E, Sato Y, Minagawa A et al. (2017):** Pathogenesis of psoriasis and development of treatment. *Journal of Dermatology*, 2 (5): 1-9
13. **Armstrong A, Read C (2020):** Pathophysiology, Clinical Presentation, and Treatment of Psoriasis A Review *JAMA.*, 323 (19): 1945-1960.
14. **Schafer P (2012):** Apremilast mechanism of action and application to psoriasis and psoriatic arthritis. *Biochem Pharmacol.*, 83 (4): 1583–1590.
15. **Bookstaver P, Norris L, Rudisill C et al. (2008):** Multiple toxic effects of low-dose methotrexate in a patient treated for psoriasis, *Am J Health Syst Pharm.*, 65 (6): 2117-21
16. **Chen X, Cheng Y, Yang M et al. (2013):** Narrow-band ultraviolet B phototherapy versus broad-band ultraviolet B or psoralen-ultraviolet A photochemotherapy for psoriasis. <https://pubmed.ncbi.nlm.nih.gov/24151011>
17. **Stern R (2007):** Psoralen and ultraviolet a light therapy for psoriasis. *N Engl J Med.*, 357 (7): 682–690
18. **Blauvelt A (2016):** Safety of secukinumab in the treatment of psoriasis. *Expert Opin Drug Saf.*, 15 (10): 1413–20.
19. **Bakshi H, Nagpal M, Singh M et al. (2020):** Treatment of Psoriasis: A Comprehensive Review of Entire Therapies. *Current Drug Safety*, 2 (1): 31-39.
20. **Talbott W, Duffy N (2015):** Complementary and alternative medicine for psoriasis: what the dermatologist needs to know. *Am J Clin Dermatol.*, 16: 147-65.
21. **Surjushe A, Vasani R, Saple D (2008):** Aloe vera: a short review. *Indian J Dermatol.*, 53(4):163–6.
22. **Bernstein S, Donsky H, Gulliver W et al. (2006):** Treatment of Mild to Moderate Psoriasis with Reli??va, a *Mahonia aquifolium* Extract???A Double-Blind, Placebo-Controlled Study. DOI: 10.1097/00045391-200603000-00007
23. **Chiang Y, Li A, Leu Y et al. (2013):** An in vitro study of the antimicrobial effects of indigo naturalis prepared from *Strobilanthes formosanus* Moore. *Molecules*, 18: 14381-96.
24. **Road B (2012):** ARTEMISIA ANNUA (QINGHAO): A PHARMACOLOGICAL REVIEW. *International journal of pharmaceutical science and researches*, 3 (12): 4573-4577.
25. **Arora N, Shah K, Pandey-Rai S (2016):** Inhibition of imiquimod-induced psoriasis-like dermatitis in mice by herbal extracts from some Indian medicinal plants. *Protoplasma*, 253 (2): 503–15.
26. **Kimmel G, Lebwohl M (2018):** Psoriasis: Overview and Diagnosis. Springer International Publishing AG, part of Springer Nature I T. Bhutani et al. (eds.), Evidence-Based Psoriasis, Updates in Clinical Dermatology, 319: 90107-7.

27. **Martinez-Correa H, Bitencourt R *et al.* (2016):** paperIntegrated extraction process to obtain bioactive extracts of *Artemisiaannua* L. leaves using supercritical CO₂, ethanol and water. *Industrial Crops and Products*, 5 (1): 44-50.
28. **https://www.researchgate.net/publication/235671908_Phytochemis...**
29. **Tungmunnithum D, Thongboonyou A, Pholboon A *et al.* (2018):** Flavonoids and Other Phenolic Compounds from Medicinal Plants for Pharmaceutical and Medical Aspects: An Overview. *MDPI journal*, 5 (1): 93.
30. **Huai M, Zeng J, Ge W (2021):** Artemisinin ameliorates intestinal inflammation by skewing macrophages to the M2 phenotype and inhibiting epithelial-mesenchymal transition. *Int. Immunopharmacol.*, 91 (10): 107284.
31. **Bernstein S, Donsky H, Gulliver W *et al.* (2006):** Treatment of mild to moderate psoriasis with Relieva, a *Mahonia aquifolium* extract: a double-blind, placebo-controlled study. *A. m J Ther.*, 13 (2): 121–6.
32. **Septembre-Malaterre A, Lalarizo Rakoto M, Marodon C *et al.* (2020):** *Artemisia annua*, a Traditional Plant Brought to Light. *Int. J. Mol. Sci.*, 21: 4986
33. **Ivense U, Steinkjer B, Serup J *et al.* (2020):** Ointment is evenly spread on the skin, in contrast to creams and solutions. *British Journal of Dermatology*, 145: 264-267.
34. **Van der Fits L, Mourits S, Voerman J *et al.* (2001):** Imiquimod-Induced Psoriasis-Like Skin Inflammation in Mice Is Mediated via the IL-23/IL-17 Axis. *The Journal of Immunology*, 182: 5836-5845.