

## Role of Sonoelastography in Evaluation of Liver Fibrosis: Review Article

Omar Ahmed Abdellatif Ahmed\*

Department of Pediatrics, Faculty of Medicine, Sohag University, Sohag, Egypt

\*Corresponding author: Omar Ahmed Abdellatif Ahmed, **Mobile:** (+20), 01025653232,

**E-Mail:** omar\_ahmed@med.sohag.edu.eg

### ABSTRACT

**Background:** Liver parenchymal cells, non-parenchymal liver cells, and infiltrating immune cells all play roles in the development and regression of fibrosis. Hepatocyte mortality through chronic causes such as apoptosis, necrosis, or necroptosis is essential. Death of cells activates inflammatory and pro-fibrogenic pathways in non-parenchymal cells and invading immune cells, which in turn triggers fibrosis advancement but may also contribute to fibrosis resolution. Patients with hepatitis C have made elastography's usefulness in the diagnosis of fibrosis a priority. Traditional treatment relied heavily on interferon injections, which can have serious adverse effects.

**Objective:** Assessment of possible role of sonoelastography in evaluation of liver fibrosis.

**Methods:** Mean Platelet Volume, Pediatrics, and Idiopathic Thrombocytopenic were all looked for in PubMed, Google scholar, and Science direct. References from relevant literature were also evaluated by the authors, but only the most recent or complete study from December 2003 to February 2022 was included. Due to the lack of sources for translation, documents in languages other than English have been ruled out. Papers that did not fall under the purview of major scientific investigations, such as unpublished manuscripts, oral presentations, conference abstracts, and dissertations, were omitted.

**Conclusion:** Patients with chronic liver illness have an alternative in sonoelastography that is safe, noninvasive, and accurate for assessing fibrosis.

**Keywords:** Sonoelastography, Ultrasound, Hepatitis C, Liver fibrosis.

### INTRODUCTION

In the last decade, elastography has become a standard method for determining liver stiffness. Hepatic fibrosis, the outcome of long-term liver injury, causes the liver to stiffen by producing an abnormally high amount of extracellular matrix via fibroblast-like cells.

Noninvasively measuring liver stiffness with elastography is possible. Ultrasound (US) or magnetic resonance imaging (MRI) can be used to monitor changes in tissue response to mechanical actuation from the outside or acoustic radiation from the inside (MRI) <sup>(1)</sup>.

Patients with chronic liver illness have an alternative in sonoelastography that is safe, noninvasive, and accurate for assessing fibrosis. Liver elastography is mostly used in the clinic for the purpose of diagnosing and classifying the severity of fibrosis in patients with chronic liver disease, as well as to follow up patients who have already been diagnosed with fibrosis or who are undergoing treatment for hepatic fibrosis <sup>(1)</sup>.

Patients with hepatitis C have made elastography's usefulness in the diagnosis of fibrosis a priority. When interferons were used as the cornerstone of therapy, patients often experienced unpleasant side effects. Polymerase inhibitor treatment for hepatitis C has reduced adverse effects and increased cure rates to around 100 percent. The high cost of therapy is a major drawback of this category of

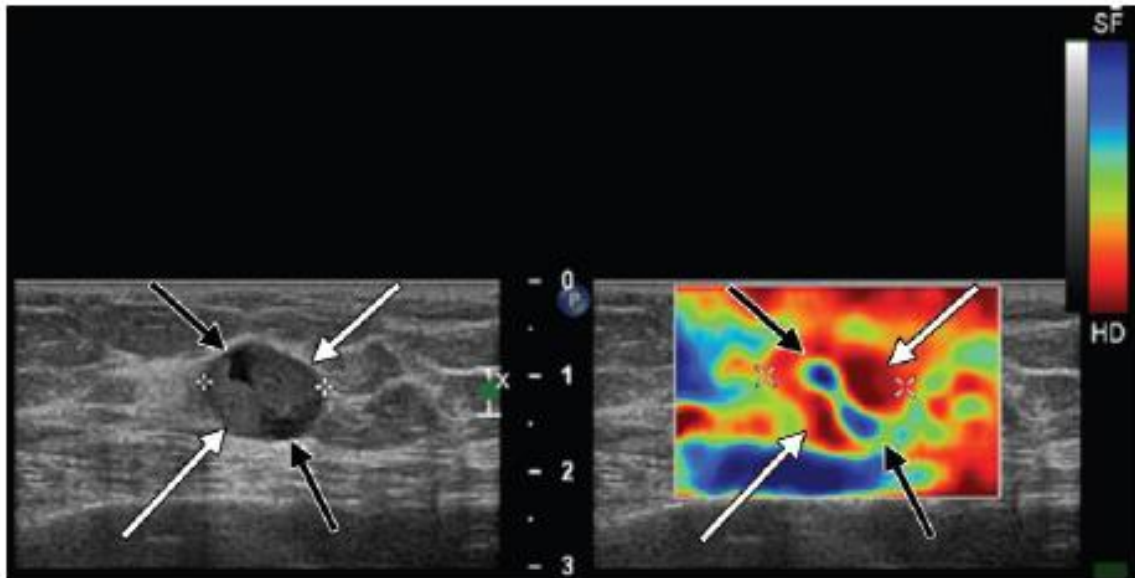
medications. Given that this medicine may only be used in patients with advanced fibrosis or cirrhosis under the present payment schemes, fibrosis staging is necessary (METAVIR F3 and above).

A primary cause of the need for a liver transplant in the United States is nonalcoholic fatty liver disease (NAFLD), the most common form of chronic liver disease. Those who develop nonalcoholic steatohepatitis and are at high risk for fibrosis progression should be identified early and monitored noninvasively. Due to its lack of invasiveness, elastography has increased use in assessing fibrosis in these individuals <sup>(2)</sup>.

### Imaging of static or quasistatic strain:

Compression elastography, sometimes known as quasistatic or static elastography, is a kind of elastography, subjects tissue to repeated compression to induce stress, and then uses color-coding to quantitatively and visually display the degree to which lesion deformation compares to that of surrounding normal tissue.

Compression can be given either manually with the transducer (quasistatic) or physiologically, when tissues around organs that are constantly in motion, such the heart and lungs, are compressed (static). A great deal of inconsistency can be attributed to the fact that the degree of compression used is subjective and difficult to measure <sup>(3)</sup>.



**Figure (1):** Elastography of strain. Left US photograph in grayscale, depicts a 1.47-cm complicated cystic and solid tumour in a lady with aggressive papillary cancer. Photo taken using strain elastography (Right) for the same patient demonstrates a heterogeneous stiffness, with the solid component (areas denoted by white arrows) seeming rigid and the cystic component (areas denoted by black arrows) appearing soft <sup>(3)</sup>.

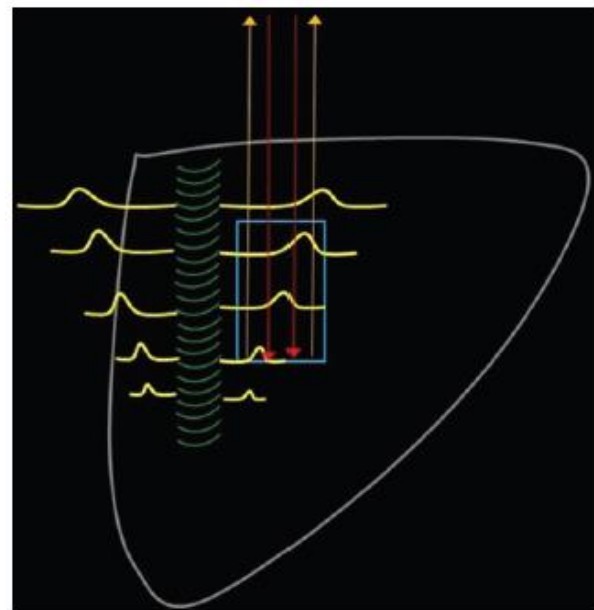
Lesion evaluation in the breast and thyroid frequently involves static or quasistatic elastography. Strain elastography had an 89% sensitivity and an 81% specificity in detecting malignancy in a sample of 367 thyroid patients with nodules. Because the intercostal space is so large and subcutaneous fat is so thick, this method is not likely to be effective in the evaluation of chronic liver sickness at this time <sup>(4)</sup>.

#### One-dimensional transient elastography:

At a measuring depth of 25 mm to 65 mm below the skin's surface, transient elastography may roughly estimate the liver's stiffness as a cylinder 1 cm broad and 4 cm long. This volume, which is one hundred times bigger than a standard liver biopsy, offers a more precise reflection of the entire hepatic parenchyma <sup>(4)</sup>. Transient elastography allows for immediate access to results, in addition to being noninvasive, rapid (taking 5 minutes), and simple to do at the bedside or in the outpatient clinic. Transient elastography has been proven to be an accurate way of assessing liver fibrosis in patients with chronic hepatitis <sup>(5)</sup>.

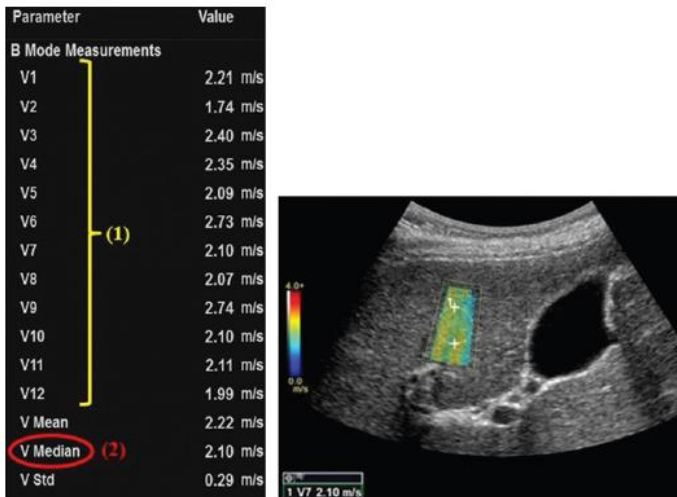
#### Point shear-wave elastography:

Tissue shear waves are produced when the probe's focused ultrasonic beams are used to reposition the tissue from the back to the front. Focused ultrasound pulses are delivered to the liver at a depth selected by the operator, producing a transverse wave (shear wave). Liver parenchyma shear wave velocities may be assessed using US tracking pulses <sup>(6)</sup>.



**Figure (2):** The five fundamental stages of point shear-wave elastography are depicted in the diagram <sup>(6)</sup>.

Transient elastography allows for rapid access to results and additionally it is painless, quick (taking 5 minutes), and easy to do at the bedside or in the outpatient clinic. Transient elastography has been proven to be a reliable approach for assessing liver fibrosis in patients with chronic hepatitis. About, 10-12 region of interests (ROIs) are consecutively chosen that include exclusively liver parenchyma. When taking measurements, the subject is asked to hold their breath while doing slow, regular breathing. Calculations for the mean, median, and average velocities are performed mechanically <sup>(7)</sup>.



V1	1.47 m/s
V2	1.54 m/s
V3	2.28 m/s
V4	2.09 m/s
V5	1.87 m/s
V6	2.35 m/s
V7	1.76 m/s
V8	1.88 m/s
V9	2.00 m/s
V10	1.96 m/s
V11	1.50 m/s
V12	2.16 m/s
V Mean	1.90 m/s
V Median	1.92 m/s
V Std	0.30 m/s

a.

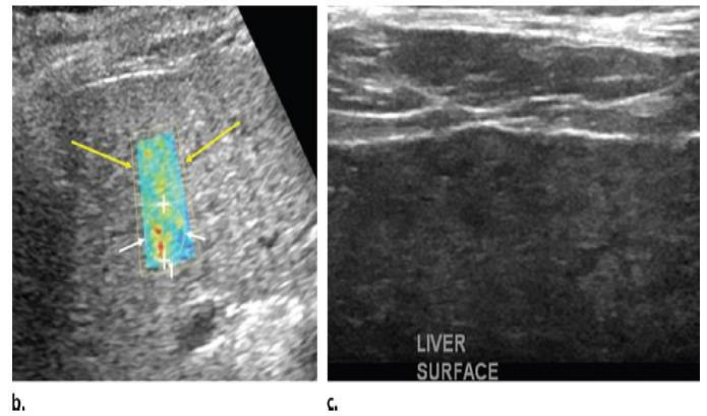
**Figure (3):** Point shear-wave elastography was used to evaluate the patient's velocities, and the results showed that the woman, aged 64, had advanced fibrosis caused by hepatitis C <sup>(7)</sup>.

**Supersonic shear-wave elastography:**

Shear-wave velocity measurement is the foundation of both transient and supersonic shear-wave elastography. In contrast, a conical shear-wave front is generated when focused US beams are continually delivered to tissue at varying depths. Supersonic shear-wave imaging has a bigger ROI (up to 50 mm 50 mm) and a fan-shaped ROI (rather than the standard square). The speed of this shear-wave front may then be determined using real-time imagery. Finding the velocity of a shear wave as it travels yields a two-dimensional representation of the environment. An ROI's viscoelastic characteristics may be seen with a colour lookup table using this method. Liver stiffness cannot be adequately assessed by transient elastography in individuals with significant obesity, thick subcutaneous fat, and ascites. This restriction can now be circumvented. Clinical practice does not yet incorporate shear-wave viscosity testing as a diagnostic tool. In addition, a grayscale US picture may be shown in the background of the elastogram using this method, making it more accessible to a physician who is more accustomed with traditional US <sup>(8)</sup>.

**Sonoelastographic interpretation:**

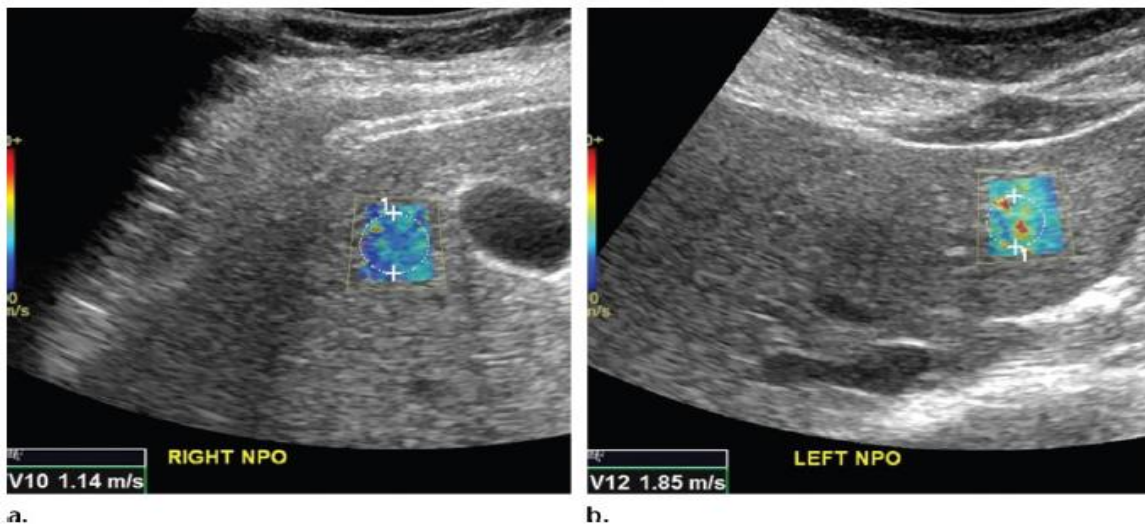
Since velocity measurements vary from manufacturer to manufacturer in the United States, fibrosis cutoff values for elastographic procedures in this country are manufacturer-specific. There may be considerable overlap of fibrosis phases between these two cutoff levels, according to research published, suggesting that such situations necessitate further testing (such as blood tests and/or a biopsy) <sup>(9)</sup>.



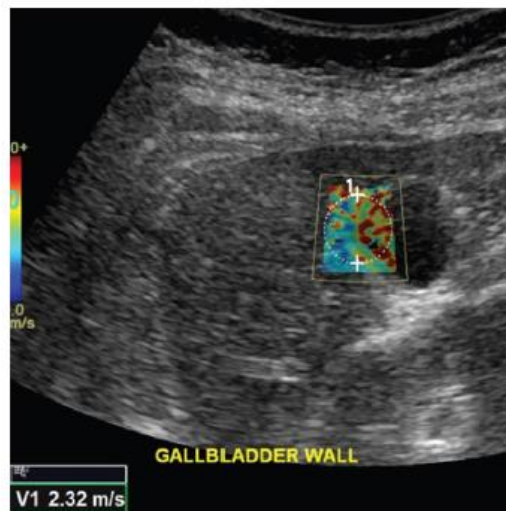
**Figure (4):** An ultrasound elastography study of a 62-years-old lady with hepatitis C and cirrhosis <sup>(9)</sup>.

**US elastographic confounders:**

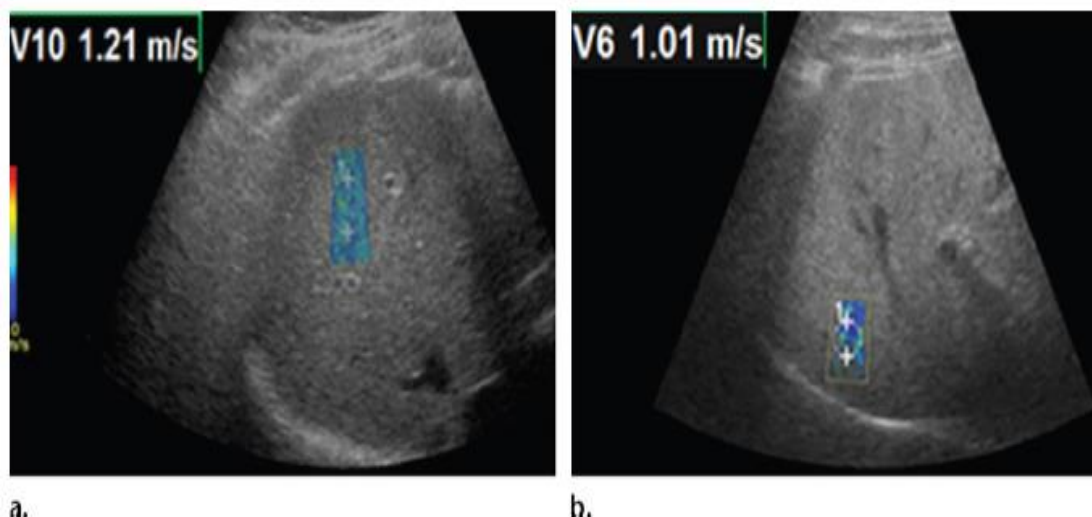
Technical confounders in US elastography pertain to hardware and operator characteristics, whereas biologic confounders involve physiologic and pathologic abnormalities in tissues that also lead to misleading results. The fact that left lobe measurements tend to provide larger velocities than right lobe readings, for instance, is a technical confounder. This false acceleration is most likely due to the left lobe's susceptibility to compression by the US probe, the stomach, or the heart. Therefore, right lobe intercostal measures are favored. The incorporation of nonparenchymal tissue inside the region of interest (ROI) is another significant technical confounder. When the liver capsule, blood vessels, gallbladder wall, falciform ligament, and bile ducts are all factored into the study, the results might be pushed upwards in terms of velocity. The lack of elasticity in the walls of nonparenchymal structures gives the impression of fibrosis and rigid tissue, which contributes to the misleading perception of an increased volume. The depth of the measurement is also very important for determining the speed. The ideal depth is between 2 and 7 cm below the liver capsule's surface <sup>(10)</sup>.



**Figure (5):** The right and left lobes of a healthy 37-years-old female volunteer were measured using point shear-wave elastography, and the findings were compared. There is a good chance that the higher velocity measured in the left lobe was caused by compression from the probe, the heart, or the stomach <sup>(10)</sup>.



**Figure (6):** Healthy 37-years-old female volunteer had spuriously higher velocity readings. The sample region (circle) in this point shear-wave elastographic picture has a measured velocity of 2.32 meters per second. Since the gallbladder wall was included in the region of interest (ROI), the measured velocity is artificially high. Since the gallbladder wall is stiffer than average, the gallbladder's velocity reading is inflated <sup>(10)</sup>.



**Figure (7):** Point shear-wave elastography was used to examine the effect of depth on the velocity values of a healthy 37-years-old female participant <sup>(10)</sup>.

Acoustic radiation force impulse (ARFI) pulses are attenuated at shallower depths depending on their amplitude, with lower amplitude pulses being attenuated more severely due to restrictions placed on them by the food and drug administration (FDA). For further in-depth shear-wave observations, pulses exceeding the threshold are required. In terms of biology, movement during breathing is a major complicating factor. It is recommended that velocities be measured while holding one's breath during a slow, typical exhalation. Measurements of stiffness may be skewed upward if the subject is deeply inspired. Alcohol, inflammation, hepatic congestion, fasting vs the postprandial state, diurnal fluctuation, and shifts in body temperature are all additional biological contributors. These elements also influence MR elastographic tests<sup>(10)</sup>.

#### **Sonoelastographic performance:**

In order to evaluate the accuracy of diagnostic tests used in the staging of liver fibrosis, the area under the receiver operating curve (Az) is often calculated. If the Az is 1.00, the diagnostic tool is considered ideal; if it's greater than 0.90, it's excellent; and if it's greater than 0.80, it's good<sup>(11)</sup>.

#### **Sonoelastographic limitations:**

Since the velocity of a shear wave depends on both the stiffness of the tissue and the frequency at which the wave is delivered, it is difficult to directly compare the stiffness values measured by different manufacturers and methods. Findings may differ even when assessing the same subject at the same time since operator expertise contributes to the procedure's accuracy<sup>(12)</sup>. Still, despite these disadvantages, US elastography is a reliable noninvasive method for assessing liver fibrosis. In addition to measuring liver stiffness, the controlled attenuation parameter approach may assess hepatic steatosis by measuring the amount of ultrasonic attenuation by hepatic fat. Using the controlled attenuation parameter as a surrogate for steatosis, this research revealed that it accurately predicted steatosis severity. Ultrasound elastography (US elastography) can provide not just anatomic imaging but also biopsy guidance, meaning it may one day replace many diagnostics. More precise evaluations of livers of variable homogeneity are possible because of the operator's ability to select region of interests (ROIs). Predictive of patient outcomes in chronic liver illness, portal hypertension must be determined in tandem with spleen stiffness measurement<sup>(12)</sup>.

#### **CONCLUSION**

Patients with chronic liver illness have an alternative in sonoelastography that is safe, noninvasive, and accurate for assessing fibrosis.

**Conflict of interest:** The authors declared no conflict of interest.

**Sources of funding:** This research did not receive any specific grant from funding agencies in the public, commercial, or not-for-profit sectors.

**Author contribution:** Authors contributed equally in the study.

#### **REFERENCES**

1. **Friedman S, Pinzani M (2022):** Hepatic fibrosis 2022: Unmet needs and a blueprint for the future. *Hepatology (Baltimore, Md.)*, 75 (2): 473–488.
2. **Jarcuska P, Bruha R, Horvath G et al. (2016):** Evaluation of hepatic fibrosis - access to non-invasive methods, national practice/guidelines in Central Europe. *Clinical and Experimental Hepatology*, 2 (1): 12–15.
3. **Srinivasa Babu A, Wells M, Teytelboym O et al. (2016):** Elastography in Chronic Liver Disease: Modalities, Techniques, Limitations, and Future Directions. *Radiographics: a Review Publication of the Radiological Society of North America*, 36 (7): 1987–2006.
4. **Matos J, Paparo F, Bacigalupo L et al. (2019):** Noninvasive liver fibrosis assessment in chronic viral hepatitis C: agreement among 1D transient elastography, 2D shear wave elastography, and magnetic resonance elastography. *Abdominal Radiology (New York)*, 44 (12): 4011–4021.
5. **Sandrin L, Fourquet B, Hasquenoph J et al. (2003):** Transient elastography: a new noninvasive method for assessment of hepatic fibrosis. *Ultrasound in Medicine & Biology*, 29 (12): 1705–1713.
6. **Barr R (2018):** Shear wave liver elastography. *Abdominal Radiology (New York)*, 43 (4): 800–807.
7. **Herrmann E, de Lédinghen V, Cassinotto C et al. (2018):** Assessment of biopsy-proven liver fibrosis by two-dimensional shear wave elastography: An individual patient data-based meta-analysis. *Hepatology (Baltimore, Md.)*, 67 (1): 260–272.
8. **Dhyani M, Grajo J, Bhan A et al. (2017):** Validation of Shear Wave Elastography Cutoff Values on the Supersonic Aixplorer for Practical Clinical Use in Liver Fibrosis Staging. *Ultrasound in Medicine & Biology*, 43 (6): 1125–1133.
9. **Schiavon L, Narciso-Schiavon J, de Carvalho-Filho R (2014):** Non-invasive diagnosis of liver fibrosis in chronic hepatitis C. *World Journal of Gastroenterology*, 20 (11): 2854–2866.
10. **Karam A, Beland M (2020):** Liver Ultrasound Elastography: Review of Techniques and Clinical Applications. *Rhode Island Medical Journal*, 103 (5): 26–29.
11. **Lurie Y, Webb M, Cytter-Kuint R et al. (2015):** Non-invasive diagnosis of liver fibrosis and cirrhosis. *World Journal of Gastroenterology*, 21 (41): 11567–11583.
12. **Tang A, Cloutier G, Szeverenyi N et al. (2015):** Ultrasound elastography and MR elastography for assessing liver fibrosis: I. Principles and techniques. *AJR Am J Roentgenol.*, 205 (1): 22–32.