

Giant Ovarian Serous Cystadenoma in a 3-Month-Old Infant – A Case Report

Hamad AlMadi¹; Hareth Aldosaimani¹; Abdullah Al-Shamrani²; Saleh A. Alshehri¹; Mohammed AlFaifi³

¹Pediatric Emergency Medicine, Prince Sultan Military Medical City (PSMMC), ²Pediatric Pulmonologist, Prince Sultan Military Medical City (PSMMC); ³Pediatric Emergency Medicine, King Faisal Specialist Hospital & Research Centre (KFSH-RC), Riyadh, Saudi Arabia.

Mobile: +966555222710, Email: dr.h.madi@gmail.com, ORCID No.:0000-0002-2611-778X

ABSTRACT

Introduction: Ovarian cysts are uncommon in live-born female newborns, with a frequency of roughly 1: 2500. Few occurrences of serous cystadenoma have been recorded, however, increasing gestational age, maternal diabetes, preeclampsia, and rhesus isoimmunization may increase the frequency of ovarian cysts.

Case report: A 3-month-old girl born 34 weeks prematurely and complaining of increased abdominal distension was brought by her mother. On abdominal computed tomography, a large unilocular ovarian cyst occupied the whole abdomen. Laparoscopic assessment indicated a pelvic ovarian cyst mass containing 1000 ml and gross examination revealed a unilocular ovarian cyst.

Keywords: Ovary, Cystadenoma, Infant, Cystectomy, Oophorectomy.

CASE PRESENTATION

A 3-month-old girl, born 34 weeks premature, was brought by her mother with complaints of increasing abdominal distension; that began for 45 days ago, she was passing normal stool, no history of fever or vomiting, she was good feeding. Vital signs were stable, distended abdomen and other clinical examination unremarkable.

Ultrasonography of the abdomen:

There was a huge abdominopelvic cystic mass extending from the right upper quadrant down to the pelvis exerting a mass effect on adjacent organs. The mass was approximately 9.4 x 13.5 x 14.8 cm corresponding to a volume of 1000 ml, with no any internal septations, solid components, or vascularization on Doppler.

Computed tomography of the abdomen showed a huge cyst occupying the entire abdomen. The unilocular cyst measured 14 x 9.7 x 13 cm in anterior-posterior, transverse, and craniocaudal directions. The cyst originates in the pelvis and displaces other abdominal

organs superiorly; and the kidneys posteriorly, resulting in posterior compression of the kidneys. No enhanced wall, solid component, fat content, or calcification within the cyst.

Differential diagnosis included large ovarian cyst; or less likely mesenteric cyst or lymphangioma.

On laparoscopic evaluation, a cystic mass in the pelvic region filled with 1000 ml of dark yellow fluid. It was aspirated and then sent for histopathological examination. The cyst originated from the right ovary and formed the entire, no solid component within the cyst, it was twisted more than twice. Detorsion was performed, the cyst was removed, preserving the fallopian tubes (**oophorectomy**).

Gross examination revealed a unilocular ovarian cyst measuring 9.0 x 5.0 cm, with no solid component and an average wall thickness of 0.2 cm. On microscopic examination, the hypocellular smear showed rare, pale looking cells against a background of debris and few macrophages.

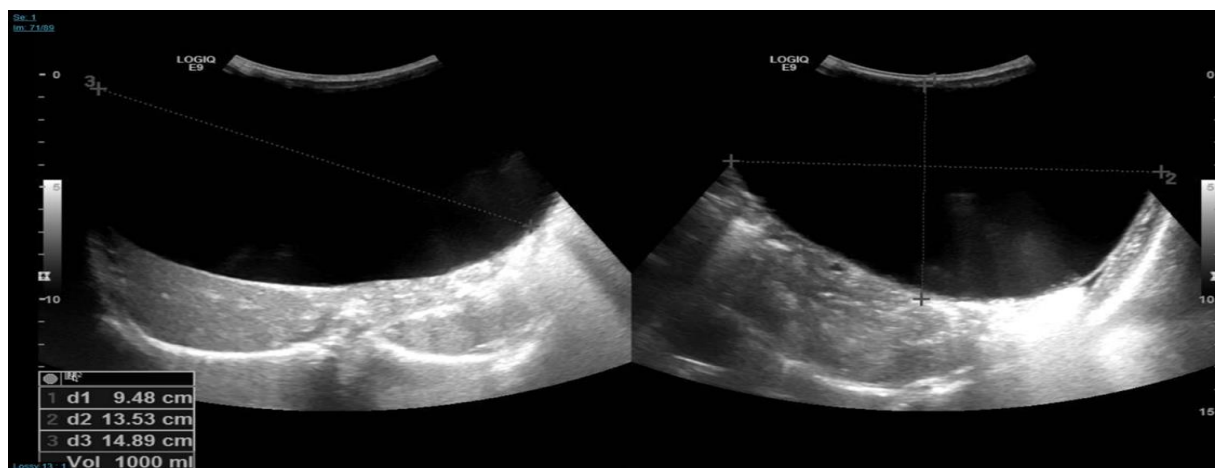


Figure (1): US of abdomen

There was an abdominopelvic cystic mass, approximately measures 9.4 x 13.5 x 14.8 cm

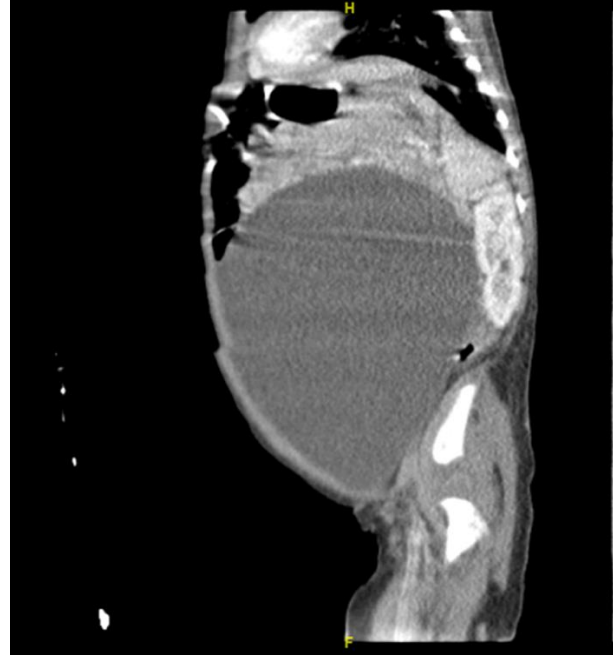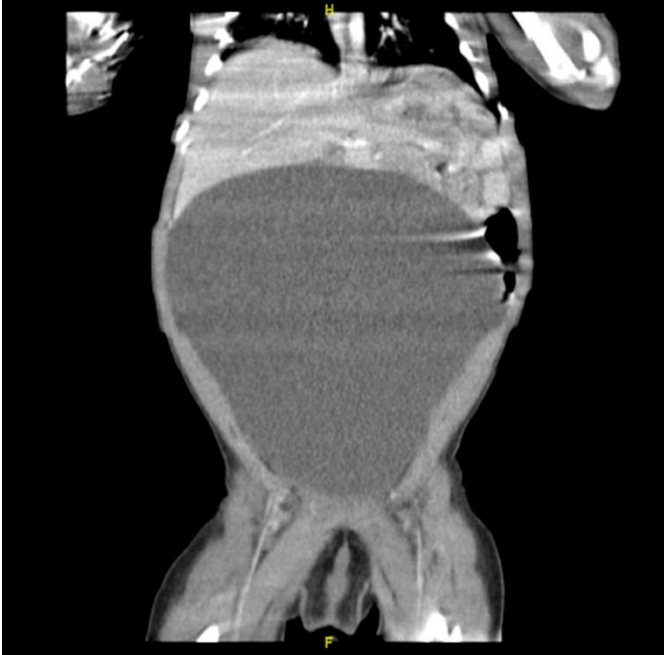


Figure (2): CT scan of the abdomen (Anteroposterior)

Figure (3): CT scan (Transverse)

Figures (2) and (3) showed that there was a huge cyst occupying the entire abdomen. Unilocular cyst measuring 14 x 9.7 x 13 cm in anterior-posterior, transverse and craniocaudal dimensions respectively.

DISCUSSION

The incidence of ovarian cysts is about 1:2500 and is uncommon in live-born female newborns. In neonates, ovarian cysts are deemed pathologic only if they exceed 2 cm in diameter. Cysts are categorized in radiological categorization as "small" (less than 4 cm) or "large" (more than 4 cm). Cysts that are pathologically complex if they have septa, debris, or other solid components. If the cyst is larger than 5 cm in diameter, problems might include torsion or rupture. The preferred course of therapy was surgical removal, either an oophorectomy or a cystectomy. For ovarian cysts, increasing gestational age, maternal diabetes mellitus, preeclampsia, and rhesus isoimmunization are risk factors that may enhance their occurrence¹⁻⁵

The majority of cases are unilateral fetal ovarian cysts, which are caused by ovarian stimulation by maternal and fetal gonadotropins, and there is no indication of an increased risk of recurrence in subsequent pregnancies^{6,7}.

Ovarian cysts are at risk of torsion, internal bleeding, and rupture, which can result in peritonitis. The large ovarian cysts may cause obstruction of the gastrointestinal or urinary tract^{8,9}.

Ovarian cysts may typically be distinguished from other cysts using ultrasound, including cysts of the

gastrointestinal system, genitourinary tract, or other cysts¹⁰.

Few cases of ovarian serous cystadenoma in babies under the age of six months have been recorded in the literature, according to our search. A case report of a 27-years-old woman who gave birth to a girl child with a cystic mass of 500 cc was reported by **Medhavi et al.**¹¹.

The histomorphologic characteristics were compatible with an ovarian serous cystadenoma.

Prenatal monitoring and surveillance are the first steps in the management of ovarian cysts, depending on their size (6 cm in diameter), to reduce the risk of complications¹.

Aspiration of large simple cysts during pregnancy may lower the incidence of complications, although it is still debatable due to the possibility of misdiagnosis¹².

We follow up with ultrasonography at delivery and then every four to six weeks until the cyst resolves⁶. It is allowed to use aspiration¹³, laparoscopic surgical removal (cystectomy), or additional surveillance if torsional symptoms or signs appears or if it does not improve after four months¹⁴.

CONCLUSION

Small follicular ovarian cysts and physiologic simple cysts are a common incidental finding on prenatal ultrasonography. Nonetheless, these individuals must be

observed postnatally and every four to six weeks until the cyst regresses to avoid any complications. Laparoscopic surgical excision is possible and safe in newborns with ovarian cysts, and is advised if the cysts expand or remain for more than four months.

REFERENCES

1. **Sakala E, Leon Z, Rouse G (1991):** Management of antenatally diagnosed fetal ovarian cysts. *Obstet Gynecol Surv.*, **46 (7): 407.**
2. **DeSa D (1975):** Follicular ovarian cysts in stillbirths and neonates. *Arch Dis Child*, **50 (1): 45.**
3. **Trinh T, Kennedy A (2015):** Fetal ovarian cyst: review of imaging spectrum, differential diagnosis, management, and outcome. *Radiographics*, **35 (02): 621–635.**
4. **Akın M, Akın L, Özbek S (2010):** Fetal-neonatal ovarian cysts—their monitoring and management: retrospective evaluation of 20 cases and review of the literature. *J Clin Res Pediatr Endocrinol.*, **2 (01): 28–33.**
5. **Aamir M, Punia H, Dalal P et al. (2015):** Conservative management of a large neonatal ovarian cyst: a case report. *J Clin Diagn Res.*, **9 (04): SD04–SD05.**
6. **Bryant A, Laufer M (2004):** Fetal ovarian cysts: incidence, diagnosis and management. *J Reprod Med.*, **49 (5): 329.**
7. **Zampieri N, Borruto F, Zamboni C et al. (2008):** Foetal and neonatal ovarian cysts. a 5-year experience. *Arch Gynecol Obstet.*, **277 (4): 303.**
8. **Siegel M (1991):** Pediatric gynecologic sonography. *Radiology*, **179 (3): 593.**
9. **Armentano G, Dodero P, Natta A et al. (1998):** Fetal ovarian cysts: prenatal diagnosis and management. Report of two cases and review of literature. *Clin Exp Obstet Gynecol.*, **25 (3): 88.**
10. **Trinh W, Kennedy M (2015):** Fetal ovarian cysts: review of imaging spectrum, differential diagnosis, management, and outcome. *Radiographics*, **35 (2): 621.**
11. **Medhavi V, Priti C, Anita N (2021):** Giant Ovarian Serous Cystadenoma in an Infant: Report of a Rare Case. *J Lab Physicians*, **13 (4): 388–390.**
12. **Catania V, Briganti V, Di Giacomo V et al. (2016):** Fetal intra-abdominal cysts: accuracy and predictive value of prenatal ultrasound. *J Matern Fetal Neonatal Med.*, **29 (10): 1691.**
13. **Kessler A, Nagar H, Graif M et al. (2006):** Percutaneous drainage as the treatment of choice for neonatal ovarian cysts. *Pediatr Radiol.*, **36 (9): 954.**
14. **Jafri S, Bree R, Silver T et al. (1984):** Fetal ovarian cysts: sonographic detection and association with hypothyroidism. *Radiology*, **150 (3): 809.**