

Percutaneous Nephrolithotomy Role in Management of Renal Stones: Review Article

Esam Aboulqasim Almahdi Zaed*, Lotfy Abdellatef Bendary,
Maged Mohamed Ali, Mohamed Salah Eldin Eldereey

Department of Urology, Faculty of Medicine, Zagazig University, Egypt

*Corresponding author: Esam Aboulqasim Almahdi Zaed, Mobile: (+20) 01090445149, E-mail: alzwagi2@gmail.com

ABSTRACT

Background: Three decades have passed since the creation of percutaneous nephrolithotomy (PNL), the medical name for the non-invasive removal of kidney stones. It has been documented that a percutaneous track was created to later aid in the removal of an intrarenal stone. When it comes to the fundamental surgical procedure, individual urologists may have their own preferences and little alterations. For a procedure to be considered the gold standard, it must be well-documented, risk-free, consistently effective, easy to teach and learn, and consistently reproducible.

Objective: Assessment of percutaneous nephrolithotomy role in managing renal stones.

Methods: Percutaneous nephrolithotomy, renal, and stones were all looked for in PubMed, Google scholar, and Science direct. References from relevant literature were also evaluated by the authors, but only the most recent or complete study from March 2010 to April 2021 was included. Due to the lack of sources for translation, documents in languages other than English have been ruled out. Papers that did not fall under the purview of major scientific investigations, such as unpublished manuscripts, oral presentations, conference abstracts, and dissertations, were omitted.

Conclusion: Stones smaller than 2 centimeters in diameter may be candidates for percutaneous nephrolithotomy (PCNL), the treatment of choice for larger stones.

Keywords: Percutaneous nephrolithotomy, Renal, Stones.

INTRODUCTION

Nephrolithiasis affects between 5% and 15% of the global population, most commonly affecting individuals in their thirties and forties ⁽¹⁾.

The procedure for PNL was developed more than 30 years ago. Percutaneous stone removal has been around since at least 2004, when it was initially reported. Since then, it has been shown to be a successful and safe method of dissolving and clearing not just tiny stones in the renal pelvis, but any intra-renal stone. Nephro-lithotomy and nephrolithotripsy are also possible abbreviations for PNL, with lithotomy referring to the removal of stones and lithotripsy to the shearing or fragmentation of stones. When it comes to the fundamental surgical procedure, individual urologists may have their own preferences and little alterations. The preferred approach should be one that has been studied extensively, can be used without risk in any setting, reliably yields desirable outcomes with predictable variability, and is simple enough to be taught and learned easily. Percutaneous nephrolithotomy is an effective treatment option for virtually all cases of renal stone obstruction. Percutaneous removal is the therapy of choice for obstructive stones that have been impacted for a long time or for stones that are regarded too large (>1.5 cm) to be appropriate for SWL, as it reduces the risk of infection and obstruction and results in more complete stone clearance ⁽²⁾.

Stones in the calyceal diverticulum, horseshoe kidney, kidney transplant recipients, and children are all treatable with PNL, despite the high degree of technical difficulties that would be expected in such cases ⁽³⁾.

Contraindications:

Patients with unresolvable coagulopathy should not undergo percutaneous nephrolithotomy. Aspirin and other blood-thinning drugs must be stopped 7 days before surgery ⁽³⁾.

Sterility of the urinary tract is required for any elective surgery. This is best accomplished by doing a urine culture, and then administering sensitivity-specific antibiotics for 5–7 days prior to the operation. Although it is ideal, it is not always possible to collect additional sterile urine for follow-up testing (e.g., indwelling nephrostomy or urethral catheter, struvite stone). Selected patients with a history of urosepsis, struvite calculi, or indwelling catheters may benefit from receiving intravenous antibiotics for 1–2 days prior to surgery. A temporary percutaneous nephrostomy can be placed to drain a clogged and infected P/C system before percutaneous entry, reducing the risk of sepsis and death in the event of untreated urinary tract infection ⁽³⁾.

Preoperative preparation:

Prior to surgery, a thorough patient medical history is required. Prior surgical history, bleeding disorders, antibiotic treatments, immunosuppression, and other potential risk factors for infection should all be specifically addressed in the questions asked. Assessing the need for a PNL is made possible by radiologic determination of stone size and collecting system anatomy. Blood electrolytes and coagulation markers must be tested in the lab. Urine screening by culture is recommended prior to surgery ⁽⁴⁾.

Patient Positioning:

While ensuring that the anaesthetized patient is not accidentally injured, proper patient placement during PNL is essential for ensuring that the collecting system is correctly punctured. Precise access to the kidney is assisted by a careful placement of the patient, which can prevent intraoperative problems, but the best position for the patient during a PNL has always been a matter of controversy. Over the course of the previous three decades, practitioners of PNL have experimented with a wide range of patient postures⁽⁵⁾. Positions for PNL were detailed in great detail, with the patient lying in a variety of orientations (supine, lateral, and prone).

A. Prone Position (PP):

(1) The Classic Prone Position:

It was anticipated that the PP would be the safest technique to avoid harm to the colon and visceral organs when PNL was first published in 1976. The method eventually became a standardised two-step process throughout the years that followed. The first step involves putting the patient in a supine position so that anaesthetic may be administered and retrograde access can be gained to the upper urinary system. The patient is turned over so that they are lying face up for the remainder of the treatment. Ventilation can be improved by placing rolled supports under and above the torso, or on both sides from the shoulder to the hip. Knees, feet, forehead, eyes, elbows, and fingers are all padded, as are the shoulders, and the elbows are positioned carefully to avoid brachial plexus injury⁽²⁾.

Lumbar region exposure is the primary benefit of the PP. The surgeon has plenty of room to make the incision, create many accesses/tracts, and work with his or her instruments. Since the PP upper pole is located more posteromedially, closer to the posterior abdominal wall, this anatomical feature makes it easier to pierce the PP upper pole⁽⁶⁾.

(2) The Reverse Lithotomy Position:

The traditional prone position for PNL had to be adjusted so that retrograde access could be made to the upper urinary tract at the same time. Lehman and Bagley reported positive outcomes using this combined strategy on three female patients in 1988. The patient is said to lie face down with their legs abducted at the hips and secured in plastic cradles that have been modified for this use at the thighs and knees. During surgery, the caudal end of the table is lowered as far as it can go. The urethra, bladder, and ureter are all easily accessible to the surgeon approaching from the tail end of the operating table with flexible instruments⁽⁷⁾.

(3) The Split-leg Prone Position:

Three years after they described the reverse lithotomy position, the same group of authors reported the split-leg PP, which improved percutaneous and transurethral access for both sexes. After the anaesthetic has taken effect, the patient is flipped over onto their

back on an endourological table equipped with split-leg adapters and anaesthetized. Legs are properly cushioned, held separately, and abducted at the hips only (no flexion). There is room for retrograde access because the genitalia are positioned towards the end of the operating table. It's standard practice to prepare and drape the genital and flank regions independently. It can be difficult to gain access to the bladder and upper urinary tract using flexible devices. According to the authors, numerous endourological operations, such as intracorporeal lithotripsy, can be carried out while the patient is in this position⁽⁷⁾.

(4) The Prone-flexed Position:

The flexed position of the patient during the surgery was described as an alternative to the traditional prone position. The space between the 12th rib and the posterior iliac crest can be widened by flexing the table 30–40 degrees after the patient has been turned to prone. This flexion counteracts the normal prone position's exaggerated anterior lordosis. Since the kidneys are moved inferiorly in the retroperitoneum, more room is made for the surgeon to work, the buttock is less likely to get in the way of the nephroscope during rigid nephroscopy through the lower pole, and the procedure is less invasive overall. Consequently, the caudal location of the puncture can be altered. However, the patient's breathing and circulation are hampered even worse in this position. There is an increase in airway pressure, a drop in cardiac index, and a possibility of temporary obstruction of the inferior vena cava⁽⁸⁾.

B. Supine positions:

(1) The Original Valdivia Supine Position:

Similar vast series of patients treated by multiple authors have been reported. It is easier for the endoscopic instruments to move when the abdominal wall is penetrated laterally, away from the lumbar muscles. Reduced danger of fluid absorption and even spontaneous clearance/washout of fragments are made possible by the tract's orientation because of the low pressure it maintains in the renal pelvis. Studies using CT imaging of the human body show that there is a much reduced chance of colon perforation when compared to the PP. This is because the intestine is not squashed against the kidneys and is instead allowed to float freely in the uncompressed belly⁽²⁾.

(2) The modified Valdivia position for simultaneous PNL and ureteroscopy:

Valdivia *et al.* detailed this adaptation to perform rigid ureteroscopy and PNL at the same time. To accommodate a rigid ureteroscope, a little modification to the traditional supine posture is made by flexing the legs on supports so that the ipsilateral leg is higher and the contralateral leg is lower. If a flexible ureteroscope is to be used, Valdivia recommends the traditional supine posture; he suggests this variation exclusively for rigid ureteroscopes⁽³⁾.

3) The Modified Flank Roll Position:

After the kidney has been punctured using local anaesthetic and sedation in the radiology department, percutaneous surgery is performed in several other departments. This was the norm in the early years of the PNL movement. For patients with an existing nephrostomy, Grasso *et al.* described a modified flank roll posture in 1993. When a preoperative evaluation indicates that the procedure can be performed retrogradely, and a percutaneous tract would serve only as a secondary access for flexible tools, these authors recommend adopting this approach. During a dorsal lithotomy, the patient's flank containing the percutaneous nephrostomy is tilted 45 degrees and cushioned so that the nephrostomy tube can be inserted. The upper limb is positioned transverse to the chest. Preparation and draping of the nephrostomy site and the genitalia occur simultaneously. This is because primary puncture and manipulations with stiff nephroscopes may be impossible because of the limited exposure of the flank ⁽⁸⁾.

(4) The crossed-leg Supine Position:

In this 2007 version of the classic Valdivia posture, the ipsilateral leg is crossed over the contralateral ⁽⁸⁾. By putting a pillow under the ipsilateral flank, the torso can be inclined at an angle of 30 degrees. The arms are extended in a fashion that's reminiscent of the classic Valdivia pose. These authors claim that crossing one's legs makes it easier to do a calyceal puncture and a nephrostomy tract dilation by increasing the distance between the lower rib and the iliac crest. Additionally, the stretching of the flank's skin and muscles facilitates the creation of a percutaneous entry point. The authors also noted that the assistant might be in a more relaxed posture close to the surgeon with this modification ⁽³⁾.

(5) The Galdakao-modified Valdivia Position:

This position was described, which has refocused the urological community's interest in supine PNL. The remarkable success rate of this positional surgery and its many benefits have been confirmed by other authors ⁽⁵⁾.

(6) The Complete Supine Position:

This method of doing percutaneous nephrolithotomy in which the patient is in a fully supine posture without any flank support and found that it was both safe and feasible for all patients. The patient lies supine at the table's edge with his or her legs outstretched and arms stretched and abducted. Similar benefits to other supine positions exist.

Upper pole puncture is also made easier by the absence of flank support, which would otherwise allow the kidney to slide cephalad. The authors advocated lung inflation to reduce renal pressure as a means to this end ⁽⁹⁾. When the patient is in a fully supine posture, the kidney is fully visible on a fluoroscopic image, unlike

in semi-supine situations, when the vertebrae obscure the view.

(7) The Flank-free Supine Position:

A new approach to nephrostomy placement was reported. Two towels are placed under the patient's shoulder and hip, angling the body to expose the flank. As the opposite arm is abducted, the ipsilateral arm is crossed over the sternum. However, by removing the supporting saline bag from the loin, the authors demonstrated the benefit of improved exposure of the flank, which would have been useful for percutaneous surgery had it been described ⁽¹⁰⁾.

(8) The Barts Flank-free Modified Supine Position:

The patient is supine with a saline bag under their rib cage and a gel pad under their pelvis to create an ipsilateral 15-degree flank tilt. In this position, the ipsilateral arm is draped across the heart. The lithotomy posture involves putting the legs in an extended position on the ipsilateral side and abducting and slightly elevating the opposite leg on the contralateral side. The 'Barts flank-free modified supine position describes this variant ⁽¹⁰⁾.

The modified lateral position for simultaneous antegrade and retrograde access—the 'Barts technique':

As an alternative to the traditional lateral position, this modified hybrid position allows for retrograde access to the upper urinary system, which has been shown to be easier in some cases. After positioning the patient in the lithotomy position, a foam wedge is used to hold the ipsilateral hemi-pelvis at a 45 degree angle. Shoulders perpendicular to the operating table, and the body turned to the contralateral side. When the trunk rotates laterally, the ipsilateral lower extremity also flexes dorsally a small amount, while the contralateral lower extremity stays fully abducted. The flank is well-exposed in this posture, allowing for a variety of puncture sites and a comfortable working angle with the antegrade tools. The puncture needle is inserted into the calyx of choice percutaneously, with the incision made close to the posterior axillary line ⁽¹⁰⁾.

Complex unilateral upper urinary tract disease can be treated by simultaneously gaining antegrade and retrograde access. Reduced patient injury and less time spent adjusting the patient are other benefits of this method. However, not every patient can use this position because it necessitates musculoskeletal mobility and flexibility of the spine. Sometimes it's difficult to get a good percutaneous access site while using fluoroscopy. There was a recent description of a similar pose, but with the legs bowed at a lower angle ⁽¹⁰⁾.

C. Split-leg Modified Lateral Position:

There are three procedures to obtain the split-leg MLP. The patient is placed in a lateral posture

perpendicular to the operating table, and the thorax is blocked with Elastoplast's band. As a second step, a rolled towel is positioned under the ipsilateral gluteus to oblique the pelvis at 45 degrees. Finally, the legs are broken and bent at the knees. The patient is positioned in this posture from the start of the operation and remains there the entire time they are under anesthesia. That's why both the retrograde and the percutaneous procedures share the same drapes ⁽¹⁰⁾.

Surgical Technique:

There are typically three primary phases to a typical PNL procedure ⁽⁴⁾:

A. Renal access.

B. Formation of the track.

C. Fragmentation and/or removal of stone:

It is also possible to do a percutaneous nephrolithotomy in two stages: first, the puncture, and then, second, track dilation and stone extraction. While, PNL has been shown to be safe for most patients when performed in a single stage, a two-stage procedure may be necessary for patients with elevated anesthesiologic risk factors or for organizational reasons ⁽⁴⁾. In the current literature review, various methods are reviewed for both the puncture and the track dilatation.

(1) Percutaneous Puncture of the Collecting System:

In order to insert a ureteral catheter, a cystoscope can be used with the patient in either the lithotomy position or the prone position supported by spreader bars following induction of anaesthesia. An indwelling urethral catheter is the preferred method for bladder drainage. Ureteral catheterization can be performed with a 5- or 6-Fr open-ended catheter, an occlusion balloon catheter, a dual-lumen catheter, or a ureteral access sheath ⁽¹¹⁾.

Which Pole to Puncture?

Whatever imaging method is employed, the urologist must choose a pole for puncture that offers the most direct route down the stone axis and, therefore, the greatest chance of successful stone removal.

An "outline-o-gram" could be a helpful tool in making this choice. Detailed stag horn calculus is displayed in figure (1).

Based on the "outline-o-gram" presented, it appears that a lower pole puncture can solve most of the mathematics. For the midpole calculus, a second puncture or a flexible nephroscope would be required. Therefore, an "outline-o-gram" can be used as a map to help pick which pole to prick and whether or not several tracks are required ⁽¹¹⁾.

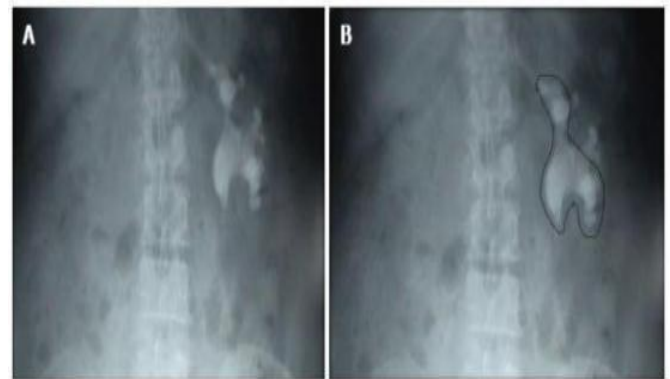


Figure (1): Outline-o-gram. (A), Left staghorn calculus by KUB; (B), Outline- o-gram

Which Calyx to Puncture?

Puncturing the posterior calyx is recommended for a safe and complication-free entry, as is stated repeatedly in the literature ⁽¹¹⁾.

Why to Puncture the Posterior Calyx?

When you puncture a calyx from the back, you'll have to go through the rather avascular Brodel's line. As an added bonus, it offers a direct route to the renal pelvis even if the patient is lying prone. Bleeding is more likely to occur if an anterior calyx is pierced since it does not pass via Brodel's line. Renal injury increases as more parenchyma must be crossed to reach the calyx. In addition, there will be a greater risk of bleeding and damage to the renal parenchyma because of the greater torque required to enter the renal pelvis at an acute angle to the infundibulum ⁽¹¹⁾.

Fluoroscopy?

Although anteroposterior radiography can help narrow down potential entrance points, it is not always accurate. When the patient is in the prone position, the anterior dependent calcaneus will be the first area to be filled with diluted contrast. As a result, the calf muscles behind you will fill up later and appear less dense. The posterior calices can be located by injecting 5-10 mL of air through the ureteral catheter while the patient is in the prone position, the air will enter the posterior calices first ^(10, 12).

Confirmation of Puncture of the Posterior Calyx:

If air was used to opacify the P/C system, aspirating the air and then injecting free-flowing saline through the ureteral catheter is the standard procedure. After that, the glide wire can be passed through the pelvis with relative ease so long as the needle angle is maintained. There's no need to manipulate anything. But if the anterior calyx has been pierced, the glide wire will be coiled in the calyx and will either not enter the pelvis at all or will require considerable effort to do so ⁽¹¹⁾.

Post-operative Care:

During and after the process, it is crucial to have a reliable estimate of irrigation and production. At the end of the percutaneous operation, patients are often given 20 mg of furosemide intravenously. Constant attention is paid to the patient's vitals, and blood counts are taken at intervals as the procedure progresses. Intravenous fluids are given at a pace that guarantees a persistent diuresis for around 24 hours after surgery. Patients with a confirmed urinary infection due to stone disease receive intravenous antibiotics for at least 48-72 hours in the hospital, and then oral antibiotics for at least until the first follow-up appointment. Within 48 hours of a simple stone removal, prophylactic antibiotic treatment can be ceased in individuals who initially had sterile urine ⁽¹²⁾.

CONCLUSION

Stones smaller than 2 centimeters in diameter may be candidates for percutaneous nephrolithotomy (PCNL), the treatment of choice for larger stones. The movement is versatile and may be performed in a number of settings. Multiple puncture methods exist now for PCNL; fluoroscopy, ultrasonography (US), and computed tomography (CT) guidance are frequently used (CT). Around the world, urologists choose fluoroscopy as their go-to for doing the percutaneous puncture.

Financial support and sponsorship: Nil.

Conflict of interest: Nil.

REFERENCES

1. **Vicentini F, Serzedello F, Thomas K et al. (2017):** What is the quickest scoring system to predict percutaneous nephrolithotomy outcomes? A comparative study among STONE score, Guy's Stone Ccore and CROES nomogram. *International Braz J Urol.*, 43: 1102-1109.
2. **Ghani K, Andonian S, Bultitude M et al. (2016):** Percutaneous nephrolithotomy: update, trends, and future directions. *European Urology*, 70 (2): 382-396
3. **Wong B (2009):** Percutaneous nephrolithotomy. *Medical Bulletin*, 14(10): 15-19.
4. **Ritter M, Krombach P, Michel M (2011):** Percutaneous stone removal. *European Urology Supplements*, 10 (5): 433-439.
5. **Hoznek A, Daels F, Kimuli M et al. (2014):** ECIRS: patient positioning and organization of the operating room: Supine percutaneous nephrolithotomy and ECIRS. Springer, Pp: 109-125. <https://link.springer.com/content/pdf/10.1007/978-2-8178-0459-0.pdf>
6. **Ray A, Ghiculete D, Pace K et al. (2010):** Limitations to ultrasound in the detection and measurement of urinary tract calculi. *Urology*, 76 (2): 295-300.
7. **Gomaa A, Abdel-maguid A, Mohamed A et al. (2018):** Comparison of the Modified Lateral Position and Prone Position Techniques in Percutaneous Nephrolithotomy. *The Egyptian Journal of Hospital Medicine*, 73 (7): 7168-7176.
8. **Karaolides T, Moraitis K, Bach C et al. (2012):** Positions for percutaneous nephrolithotomy: Thirty-five years of evolution. *Arab Journal of Urology*, 10 (3): 307-316.
9. **Falahatkar S, Enshaei A, Afsharimoghaddam A et al. (2010):** Complete supine percutaneous nephrolithotomy with lung inflation avoids the need for a supracostal puncture. *Journal of Endourology*, 24 (2): 213-218.
10. **Proietti S, Rodríguez-Socarrás M, Eisner B et al. (2019):** Supine percutaneous nephrolithotomy: tips and tricks. *Translational Andrology and Urology*, 8 (4): 381-388.
11. **Sharma G, Maheshwari P, Sharma A et al. (2015):** Fluoroscopy guided percutaneous renal access in prone position. *World Journal of Clinical Cases*, 3 (3): 245-49.
12. **Esperito F, Prata F, Aufrán-Gómez A et al. (2021):** New Technologies for Kidney Surgery Planning 3D, Impression, Augmented Reality 3D, Reconstruction: Current Realities and Expectations. *Current Urology Reports*, 35: 1-9.