

Classical Isolated Scrotal Kaposi's Sarcoma in Non-HIV Patient Case report from KAUH, Jeddah, Saudi Arabia

Mohamed Emad Bayoumi

King Abdulaziz University, Jeddah, Saudi Arabia

Corresponding author: Mohamed Emad Bayoumi, Phone number: +966500820806, Email: mohammed.e.b@hotmail.com

ABSTRACT

Background: Kaposi Sarcoma (KS) is a rare neoplastic vascular disorder. The pathogenesis of KS remains controversial. However, suppression of the immune response was almost necessary. Classical KS most likely affects the male genitalia. Penile KS is the most common, while isolated scrotal KS has been unusual to see. In this case report, we review a rare case of scrotal KS in a non-HIV patient with history, clinical, laboratory, imaging findings.

Presentation of Case: A 60 years old male patient, known to have ischemic heart disease. Presented with progressive painful scrotum swelling for 3 weeks. He had dysuria and gave a history of weight loss. Not complaining of prostate disease. By examination, there were swelling, warmth, tenderness to palpation in his scrotum. A biopsy was taken which was shown a Kaposi sarcoma.

Discussion: Despite it names as a sarcoma, it is not considered a real sarcoma because the tumour does not arise from mesenchymal tissue. It arises from endothelium tissue. The pathogenesis of KS still not clearly understood and remains controversial. However, what we know is all forms of KS are strongly associated with HHV-8 infections. The partial or complete suppression of the immune response was almost necessary. Therefore, KS is usually associated with HIV infection. KS of the scrotum has been reported in non-HIV patients. Very few cases have been presented with scrotal KS. First reported case of an isolated scrotal KS around the world was in 1976. While In 1979 had been the first time to performed total scrotoectomy and bilateral orchiectomy for scrotal KS patient. A Turkish study In 2011 reviewed only one patient had scrotal KS out of 32 cases with HIV-negative KS in the Middle East. In this case, the patient received 3 cycles of chemotherapy with no improvement so we preferred local excision because these lesions were small and stable for about 3 years. After 3 years of follow-up no recurrence was observed.

Conclusion: Classical KS is generally observed in the lower extremities, it can rarely affects scrotal skin as isolated lesions. Thus. Genital examination should also include for those patients. In addition, the isolated scrotal Kaposi sarcoma is absolutely cannot be cured by medication. Adjuvant chemotherapy still in many cases show incomplete improvement. Orchiectomy might be the conclusive curative option.

Keywords: Kaposi; Sarcoma; Scrotum; HHV-8.

INTRODUCTION

Kaposi sarcoma defines as a spindle cell tumour derived from endothelium lesions. This systemic disease associated with human herpes virus 8 (HHV-8) can hump a variable clinical course ranging from Less mucocutaneous disease to extensive organ involvement. Kaposi sarcoma can be initially classified into 4 subtypes: Classic Kaposi sarcoma, Immunosuppression-associated Kaposi sarcoma, Endemic Kaposi sarcoma, AIDS-associated Kaposi sarcoma^[1,2]. A research in 2014 studied the reported cases of KS for the period 1971–2014. They identified 44 reported cases of scrotal KS: 6 with HIV-seropositive patients, 29 in HIV-seronegative patients, and 9 patients was unspecified HIV status. Excisional biopsy and histology (including intralesional HHV-8 testing) were performed in all cases to reach the correct diagnosis. HIV-seropositive patients had

presented more severe including ulceration and multiple lesions which were extending to the groin, and non-misshapen nodules. Treatment for these patients has included the maximising highly active antiretroviral therapy (HAART). The other patients (with HIV negative or unspecified HIV), received a local treatment performed in 55.3 % (21 out of 38) of cases. Average follow-up was 14.2 months with local recurrence in two cases (2 out of 38, 5.3 %) and distant recurrence in five cases (5 out of 38, 13.2 %). In also, 6 cases reports of genitourinary KS in HIV-positive patients were reported. These cases had presented more severe including discoloured nodules, multiple ulcerated lesions, lesions extending to the groin area, penis deformity and urethral stricture deformity. More chemotherapy treatment endeavoured in addition to a maximum dose of HAART. Penile KS is a virus-induced neoplasm mainly affecting men

with HIV-seropositive, have other forms of immunosuppression^[3].

Classical KS most likely affects the lower extremities. Penile KS is the most common, while isolated scrotal KS has been unusual to see. In this article, we present a rare case presented with Kaposi's sarcoma localised to the scrotum in a non-HIV patient with history, physical examination, and laboratory findings. Excision of the scrotum with bilateral orchiectomy was performed, with uneventful recovery.

Literature was reviewed on Kaposi's sarcoma originating in the male external genitalia^[4].

CASE REPORT

Mr. Bجلي is a 60 years old Yamani male patient, known case of hypertension and ischemic heart disease.

Admitted as a case of Kaposi Sarcoma in the scrotum, he has admitted electively to another hospital about 3 months ago, he had a skin lesion and scrotal lump, a biopsy was taken which was shown a Kaposi sarcoma, after that from that time until now he did not receive any chemotherapy.

His scrotum is swollen and painful and preventing him from the walk. Also, the swelling is progressive and has difficulty in urination with the warmth of the scrotum.

He did not have pain in the loins but has discomfort which is on and off and increase with urination, he did not give a history of the prostate.

He gave a history of weight loss of 3-4 kg in the last 2 months and decreased in appetite. The patient was presented to the emergency department with recurrent chest pain.

He had a history of hypertension, dyslipidemia, ischemic heart disease. admitted 5 times ago with NSTEMI (Non-ST-segment elevation myocardial infarction), Percutaneous Coronary Intervention to LM done with 1 DES. The patient had a positive family history of tumor . his sister died of tongue cancer 2 years ago. Socially, the patient is not working (retired) and he is not a smoker.

Clinical Findings

- On examination: the patient was vitally stable
- Scrotum exam: By inspection, there was swelling and redness in the scrotum Left side patch (due to excision) By palpation: There were a warmth scrotum and tenderness to palpation
- Cardiovascular examination: Normal S1 and S2, no added sound
Respiratory examination: Bilateral equal air entry, no added sound
Abdominal examination: Soft and lax abdomen, no organomegaly

DIAGNOSTIC ASSESSMENT

Laboratory findings

CBC

Test name	Value	Normal range
RBC	5.15	4.00 – 6.00
Hb	13.7 g/dl	14.0 – 18.0
MCV	78.6 fL	80 – 94
MCH	26.6 Pg	32 - 36
Automated neutrophils	49.9 %	50 – 70
Automated Monocytes	11.3	2 - 11
Automated Eosinophils	8.2 %	1 - 3

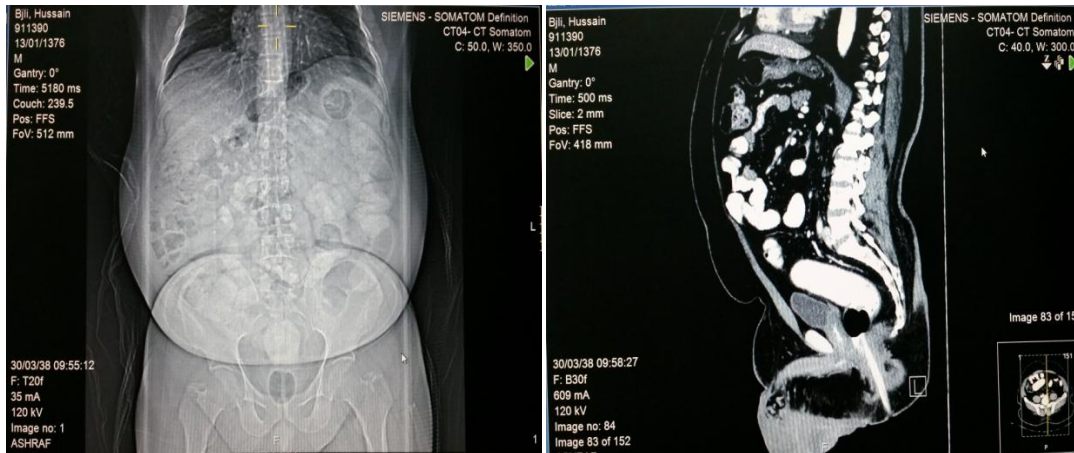
U&E :

Test name	Value	Normal range
Na+	142 mmol/L	135 – 145
K+	4.3 mmol/L	3.5 - 5
Chloride	102 mmol/L	96 - 106
Urea	4.7 mmol/L	2.5 – 6.7
Creatinine	62 umol/L	68 – 150
PTT	23.7 sec	25 - 35

- Antibody screen: negative
- Histopathology study: scrotal skin lesions, excision biopsy specimen: malignant vascular neoplasm nodules with features suggestive Kaposi's sarcoma.

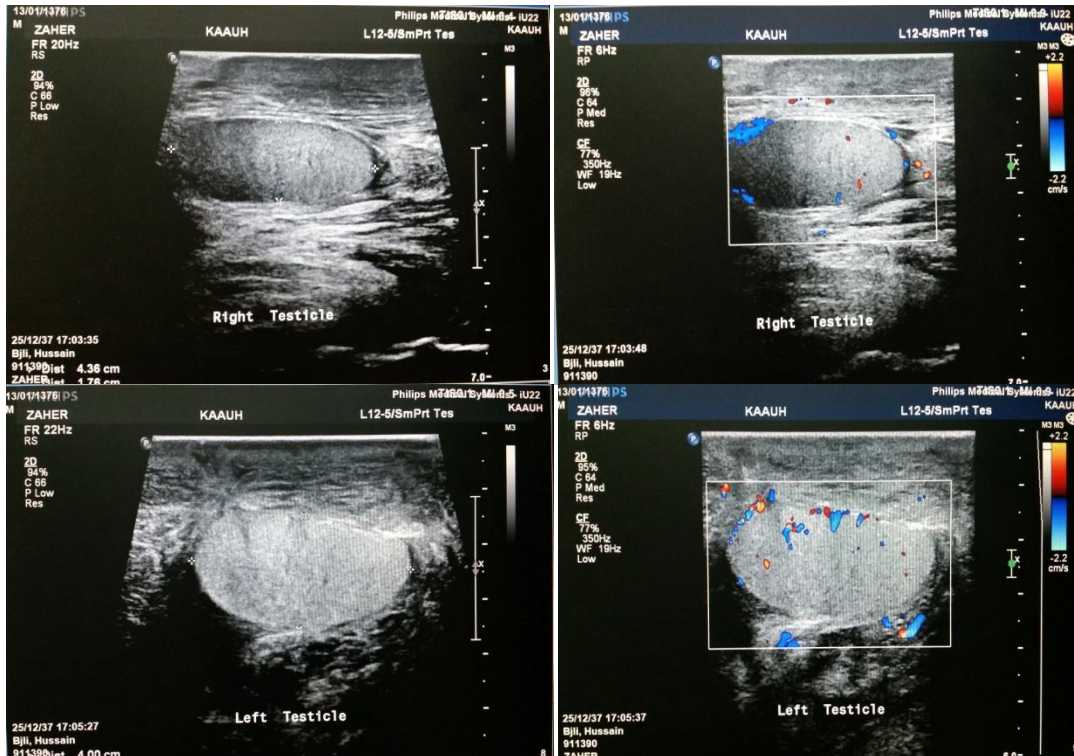
RADIOGRAPHY FINDINGS

CT of the abdomen



- shown bilateral hydrocele with internal increasing in the size and thickness and soft tissue appendages at the left side of the scrotal sac.
There is a nodule seen in the left testicle measured less than 5 mm.
- Multiple bilateral enlarged inguinal lymph node (most likely metastasis).
- Stable size left para-aortic metastatic lymph node, measuring up to 1.2 cm.
- The liver, spleen, pancreases and adrenal gland appear unremarkable, no focal lesion.
- No free air or collection.

Ultrasound of scrotum



- Both testicles are normal in size, location and echo texture with no focal solid or cystic masses. Large right sided hydrocele with multiple internal echoes suggesting infected fluid.
- significant thickening of the scrotal skin measured about 5 cm.
- 2 small hypoechoic solid nodule with the calcified centre is seen anterior to the left testicle which could be related to calcified/necrotic lymph nodes.

Therapeutic Intervention

Pharmacologic

- Acetylsalicylic Acid 81 mg Tablet (Aspirin)
- Clopidogrel 75 mg Tablet
- Chemotherapy (Docetaxel - single agent)
- NaPo₄ + NaHPo₄ (Fleet Enema-Adult)
- Omeprazole 20 mg Capsule
- Paracetamol 500 mg Tablet
- Pentoxifylline 400 mg Tablet (TRENtal)
- Perindopril 5 mg Tablet (Cover syl)
- Dexamethasone HBr 15ml/5ml syringe
- Enoxaparin Na 8000 unite/0.8 ml syringe

Follow-up

Systemic chemotherapy 3 cycles of Docetaxel every 3 weeks.

CT abdomen and pelvis after 3 months follow-up

DISCUSSION

Lesions of classical KS are most likely affects the lower limb, and the involvement of external genitalia usually is less common. Although many cases of HIV negative patients have been reported in which the penis is primarily involved, very few cases of scrotal KS have been presented. In a recent study, only one patient had a scrotal KS out of 32 cases with HIV-seronegative KS. Also, it was unclear that this single case of scrotal KS was associated with other locations or not ^[5]. Penile KS has been reported more widely. In 1976, first reported case was an isolated case of scrotal KS. Then, other three cases of isolated scrotal KS were reported ^[6]. In this case, we represent the 5th case up to our knowledge.

The pathogenesis of KS still not clearly understood and remains controversial. However, what we know is all forms of KS are strongly associated with HHV-8 infections ^[7]. The partial or complete suppression of the immune response was almost always necessary. Therefore, KS is usually associated with HIV infection. KS of the scrotum has been reported in non-HIV patients. Very few cases have been presented with scrotal KS. In this case, the patient has been received cycles of chemotherapy that might affect his immunity.

The violaceous erythematous lesions seen in KS have variants morphologies: patch, plaque, nodular, macular, and exophytic. The cutaneous lesions can be localised, solitary, or disseminated.

The common morphological subtype in KS is the lymphangioma-like type. Despite lymphedemas are generally observed in this subtype, but there was no oedema observed in the lymph in our case.

According to study took place in Greece in 2006, the researchers reported asymptomatic gastrointestinal involvement especially in the stomach in 82% of patients who diagnosed with classical KS. Therefore, they recommended schedule endoscopy for newly diagnosed KS patients ^[8]. In our case, the patient does not have systemic lesions on endoscopy and radiological imaging. Comprehensive physical examinations also revealed no other skin lesions.

Many studies conducted and led for the treatment for KS are generally performed on HIV patients. Unfortunately, currently, Kaposi sarcoma is not curable and there is no cure or treatment method capable of eradicating HHV-8. For this reason, the main goal of KS treatment is to control the symptoms of the disease, to reduce the size and number of endothelium and visceral lesions, and to slow or stop or delay the progression of the disease. Despite the use of various local and systemic treatment modalities for classical KS, there is no standard treatment method administered to genital KS." A study in 2012, studied a total of 19 patients were reported with penile KS. Local excision was done on 9 patients, circumcision was performed on 1 patient, and chemotherapy, radiotherapy, or interferon-alpha treatment in addition to local excision was performed on 3 patients. During the follow-up period, only 4 cases with local excision relapsed" ^[9]. In 1976 was the first time performed total scrotoctomy and bilateral orchiectomy in their case report with scrotal KS ^[10]. We preferred local excision for our patient because these lesions were small and stable for about 2 years. No recurrence was observed after 2 years of follow-up.

In conclusion, classical KS is generally observed in the lower extremities, it can rarely affect the scrotal skin as isolated lesions. Therefore, a careful physical examination should also include scrotum for these patients. In addition, Isolated scrotal Kaposi sarcoma is incurable disease by medication. Chemotherapy is a useful adjuvant therapy for treatment of small and localized scrotal KS but still unfit for some cases where it shows incomplete improvement. Bilateral orchiectomy might be the definitive cure.

Ethical approval

A written consent form was filled and submitted by the patient. The study was done after approval of ethical board of King Abdulaziz University.

REFERENCES

- 1. Tan W C, Chan L C (2011):** Kaposi's sarcoma : case report and treatment options. *Med J Malaysia*, 66(4):383–384.
- 2. Aktas E, Güler E, Utaş S, Deniz K, Orhan O, Yıldız O G (2008):** Penile Kaposi's sarcoma in an HIV negative male patient. *Turkderm*, 4(2):131–133.
- 3. Ozmen H, Baba D, Kacagan C, Kayikci A, Cam K (2014):** Case report: HIV negative isolated scrotal Kaposi's sarcoma. *International Journal of Surgery Case Reports*, 5(12):1086-1087.
- 4. Kolios G, Kaloterakis A, Filiotou A, Nakos A, Hadziyannis S (1995):** Gastroscopic findings in Mediterranean Kaposi's sarcoma (non-AIDS) *Gastrointest Endosc.*, 42:336–339.
- 5. Jones J L, Hanson D L, Dworkin M S, Jaffe H W (2000):** Incidence and trends in Kaposi's

sarcoma in the era of effective antiretroviral therapy. *J AIDS.*, 24: 270-4

- 6. Braun M (1982):** Classics in oncology. Idiopathic multiple pigmented sarcoma of the skin by Kaposi. *CA Cancer J Clin.*, 32:340–347.
- 7. Chan J, Kravcik S, Angel J B (1999):** Development of Kaposi's sarcoma despite sustained suppression of HIV plasma viremia. *J AIDS.*, 22: 209-210.
- 8. Balachandra B, Tunitsky E, Dawood S, Hings I, Marcus V A (2006):** Classic Kaposi's sarcoma presenting first with gastrointestinal tract involvement in a HIV-negative Inuit male – a case report and review of the literature. *Pathol Res Pract.*, 202:623–626.
- 9. Rescigno P, Di Trollo R, Buonerba C, De Fata G, Federico P, Bosso D (2013):** Non-AIDS-related Kaposi's sarcoma: a single-institution experience. *World J Clin Oncol.*, 10:52–57.
- 10. Johnson D E, Chica J, Rodriguez L H, Luna M (1977):** Kaposi's sarcoma presenting as scrotal ulcerations. *Urology*, 9 (6):686–688.