The Egyptian Journal of Hospital Medicine (January 2014) Vol. 54, Page 36– 40

Adult Neuroblastoma: A Case Report

Majed Al-Mourgi
College of Medicine, Department of Surgery Taif University, Saudi Arabia

ABSTRACT
Adult Neuroblastomas are rare tumors and pelvic type represents less than 5% of these tumors. Here, I will report the case of 38-year old Saudi female patient with adult pelvic neuroblastoma.
Results: the patient presented to the outpatient clinic with lower abdominal discomfort and distension for 6 months duration. Examination revealed large pelviabdominal mass of limited mobility. Laboratory findings were within normal, however, CT scan and MRI, revealed retroperitoneal tumor shifting the pelvic organs anteriorly and to the right. The tumor was resected completely through anterior midline approach. Pathological diagnosis revealed that the tumor was a neuroblastoma. The patient received 6 courses of chemotherapy and follow up for more than 6 years revealed no recurrence or metastasis. Though the outcome of adult neuroblastoma is poor, complete surgical resection with postoperative chemotherapy may improve the survival; however, a long-term evaluation of adult neuroblastoma is mandatory.
Key words: pelvic adult neuroblastoma, Saudi female, combined approach.

Introduction

Neuroblastoma is the commonest intra-abdominal pediatric solid tumor and has been detected in less than 10% of cases of patients above 10 years old [1-3]. The pelvis is neuroblastoma is uncommon site (< 5%), but it has a more favorable prognosis; though, recent studies have verified that adult and pediatric patients with neuroblastoma achieve similar survival outcomes, with good prognosis for early-stage patients[1, 4, 5]. The origin tumor is the neural crest cells, particularly from the adrenal medulla, but other sites reflecting the distribution of the sympathetic nervous system may be involved [1].As the tumor is rare in adults, there is a lack in prospective treatment trials, so, the pediatric protocols of treatment are usually applied but with less favorable outcome[6-9]. In this report; I will present a case of adult Saudi female patient presented by chronic left lower limb pain due to pelvic Neuroblastoma.

Case report: A 38-year-old Saudi woman presented to the outpatient clinic of Al Hada Military Hospital, Taif, Saudi Arabia in January 2007with lower abdominal discomfort and distension for 6 months duration. The condition was associated with urinary troubles in the form of day and night frequency and attacks of dysuria, but no change in urine color or stream. The patient complained also from marked dyspareunia. There is no change in bowel habits and no other abdominal complaint. The systemic review was unremarkable. General examination showed no abnormality and abdominal examination revealed irregular large pelvi-abdominal mass of irregular surface and limited mobility. Vaginal examination was painful and revealed the presence of the mass pushing vagina and other pelvic organs anteriorly and to the right side.The laboratory findings were within normal. Intravenous urography revealed compressed urinary bladder and dilated left ureter but with no other abnormalities. Pelvi abdominal CT showed pelvi-abdominal mass of 17x14x19 centimeters compressing the uterus and the vagina with shift of the pelvic structures anteriorly and to right side (Figure 1). Magnetic resonance study revealed that the mass was composed of solid, necrotic, and degenerated areas (Figure 2). The CT and MRI findings suggested retroperitoneal schwannoma versus plexiform malignant peripheral nerve sheath tumor (MPNST), however, other possible retroperitoneal tumors were not excluded. The patient and her family were counseled for resection of the tumor and they were informed about the operation with all the expected risks and possible complications. They gave a written high risk informed consent. During operation; a midline incision was done, the pelvic organs were mobilized and the parietal peritoneum covering the mass was incised and the mass was dissected from all surrounding structures

DOI: 10.12816/0002429

(Figure 3) with careful dissection from the ureter and iliac vessels down to its presacral origin and it was completely resected. The wound was closed and the resected masse was sent for pathological examination. A histopathological examination of the tumor showed a cellular tumor composed of pleomorphic cells with vesicular nuclei with picture suggestive of neurological differentiation. Immunostaining showed that the tumor was positive for CD56 (Figure 4) and synaptophysin, so, the diagnosis of neuroblastoma was made. In the 4th postoperative day, after the diagnosis was established, vanillyl mandelic acid (VMA) level was measured and found to be 19 mg (normal up to 12 mg); however, it was returned to normal range after one week. Postoperative course was uneventful and the patient was discharged after 12 days. Whole-body metaiodobenzylguanidine (MIBG) scan and bone marrow biopsy were normal with no evidence of residual tumor or metastases. The patient received 6 cycles of combination chemotherapy, with 3 weeks interval between each cycle. Each cycle included; doxorubicin; 60 mg/m^2, cisplatinum; 100 mg/m^2, cyclophosphamide 1500 mg/m^2, vincristine; 2 mg, and etoposide;16 500 mg/m^2. Follow up for more than 6 years, revealed no recurrence or metastasis.

Discussion: Reports of adult neuroblastoma are rare as 90% of cases occur after the age of 10 years [(1)]. The current case was Saudi female patient aged 38 year-old.

The tumor site is related to the distribution of neural crest cells in the different parts of the sympathetic system particularly the adrenal medulla, and pelvic tumors are detected in less than 5% of cases [(1-3)].The presentations of adult neuroblastoma are similar to pediatric type with higher incidence of metastases in lung and brain. In this case; the pelvic location of the tumor led to chronic lower abdominal discomfort, dysuria with frequency, and dyspareunia but no metastases were detected.

Neuroblastoma is a rare cause of pelvic masses, however, when an adult presents with a large solid pelvic mass, neuroblastoma should be considered as a part of the differential diagnosis [(5)].Elevated levels of catecholamines or their metabolites as dopamine, homovanillic acid (HVA), and/or vanillyl mandelic acid (VMA) are detected in the urine or blood of about 90% of cases, in addition, metaiodobenzylguanidine (MIBG) is taken up by more than 90 of all neuroblastomas[(5, 6)]. In the current cases the heterogeneous appearance of the tumor and its relation to the sacrum made the ancient schwannoma or MPNST to be the first differential diagnosis, so, the biomarkers of neuroblastoma and MIBG scan were not done except postoperatively after pathological establishment of the tumor diagnosis.

Histopathological diagnosis is the only measure for accurate diagnosis and surgical resection is the only accurate approach for pathologic evaluation to enable diagnosis of pelvic neuroblastoma [(5-7)].This is what occurred in this case.

The neuroblastomas are typically composed of pleomorphic cells with spindle shaped vesicular nuclei and the cells are usually small, round and blue with abundant febrile matrix and sometimes , Homer-Wright rosettes may be seen indicating neurological differentiation[(1-3)]. Immunostaining results show that the tumor is usually positive for NB84, in addition to primitive neural or neuroectodermal neoplasmic features as; positivity to CD56, CD99, bcl-2, or/ and neuron-specific enlace (NSE)[(5, 6)]. A histopathological examination of the present tumor showed a cellular tumor composed of pleomorphic cells with vesicular nuclei with picture suggestive of neurological differentiation. Immunostaining showed that the tumor was positive for CD56 confirming the diagnosis of neuroblastoma.

Due to the rarity of the adult forms of the tumor, the pediatric protocol of the treatment is applied which include surgical resection, chemotherapy or radiotherapy[(7-11)].Surgical excision of the pelvic neuroblastoma is a challenge for the surgeon due to the intimate relation to surrounding pelvic vessels, nerves, and other structures, and various approaches are described [(10)]. In the current case the tumor was completely excised preserving the other pelvic structures through an anterior and midline approach.

Many chemotherapeutic agents were described for treatment of adult neuroblastoma and it is suggested that the combination of cyclophosphamide, cisplatinum, doxorubicin, carboplatin and ifosfamide have the best results, but with less favorable response than in children [(7-9)]. These chemotherapeutic agents were used in this case.

Other chemotherapeutic agents which are used in other malignancies as topotecan, irinotecan, and temozolomide are now being studied for use against neuroblastoma in addition to more recent agents as, bortezomib, vorinostat, nifurtimox, and lestaurtinib [8, 9]. High dose combination chemotherapy followed by stem cell transplantation may be valuable and some clinical trials proved the effectiveness of using different combinations of chemotherapy, radiation therapy, retinoids, and other treatments as targeted therapy [9]. Targeted therapy includes; crizotinib, that target the cells with altered ALK gene and monoclonal antibody ch14.18, which targets GD2 on neuroblastoma cells, these drugs are now used routinely for patients with high-risk disease [9-10].

It was found that pelvic tumors and patients with localized disease or locally advanced disease had better survival than those with advanced metastatic disease [10, 11].In this patient the tumor was huge but no metastasis was detected. Follow up for more than 6 years revealed no recurrence or metastases. However, a 10 years follow up is recommended in adults [4, 7-11]. To conclude; though the outcome of adult neuroblastoma is poor, complete surgical resection with postoperative chemotherapy may improve the survival; however, a long-term evaluation of adult neuroblastoma is mandatory.

References

1. **Esiashvili N, Goodman M, Ward K, Marcus RB Jr, Johnstone PA (2007).**Neuroblastoma in adults: incidence and survival analysis based on SEER data. Pediatr Blood Cancer, 49: 41-6.
2. **Simon T, Berthold F, Borkhardt A, Kremens B, De Carolis B, Hero B, (2011).** Treatment and outcomes of patients with relapsed, high-risk neuroblastoma: results of German trials. *Pediatr. Blood Cancer*, 56: 578–83.
3. **Moroz V, Machin D, Faldum A *et al.* (2011).** Changes over three decades in outcome and the prognostic influence of age-at-diagnosis in young patients with neuroblastoma: a report from the International Neuroblastoma Risk Group Project. Eur. J. Cancer, 47:561–71.
4. **Conter HJ, Gopalakrishnan V, Ravi V, Ater J, Patel S, Dejka M. Araujo DM, (2013).** Are adult and pediatric neuroblastoma clinically different entities? J Clin Oncol., 31: 13013-8.
5. **London WB, Castleberry RP, Matthay KK *et al.* (2005).** Evidence for an age cut off greater than 365 days for neuroblastoma risk group stratification in the Children's Oncology Group. J. Clin. Oncol. 23: 6459-65.
6. **Conte M, Parodi S, De Bernardi B, Milanaccio C,Mazzocco K, Angelini P *et al.* (2006).**Neuroblastoma in adolescents: the Italian experience. Cancer, 106: 1409-17.
7. **London WB, Frantz CN, Campbell LA *et al.*(2010).**Phase II randomized comparison of topotecan plus cyclophosphamide versus topotecan alone in children with recurrent or refractory neuroblastoma: a Children's Oncology Group Study. J. Clin. Oncol.,28: 3808–15.
8. **Simon T, Langler A, Berthold F, Klingebiel T, Hero B (2007).** Topotecan and etoposide in the treatment of relapsed high-risk neuroblastoma: results of phase 2 trial. J Pediatr Hematol Oncol., 29: 101-6.
9. **Kushner BH, Kramer K, LaQuaglia MP, Modak S, Cheung NK (2003).**Neuroblastoma in adolescents and adults: The Memorial Sloan-Kettering experience. Med Pediatr Oncol ., 41: 508-15.
10. **De Bernardi B, Mosseri V, Rubie H *et al.* (2008).** Treatment of localized resectable neuroblastoma. Results of the LNESG1 study by the SIOP Europe Neuroblastoma Group. Br. J. Cancer, 99: 1027–33.
11. **Kajbafzadeh AM, Sadeghi Z, Esfahan SA, Fisher C, Judson I (2011).**Adult pelvic neuroblastoma: long-term survival and review of the literature. Turkish Journal of Urology, 37(2):167-71.

Figure 1: CT scan showing huge pelvic tumor with shift of the pelvic organs anteriorly and to the right

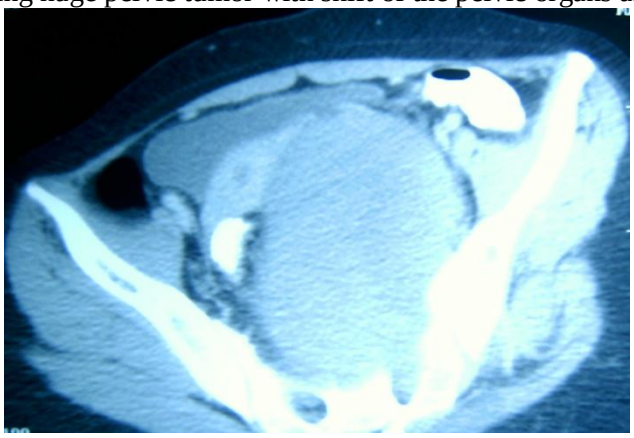

Figure 2: MRI showing huge pelvic tumor with heterogeneous contents

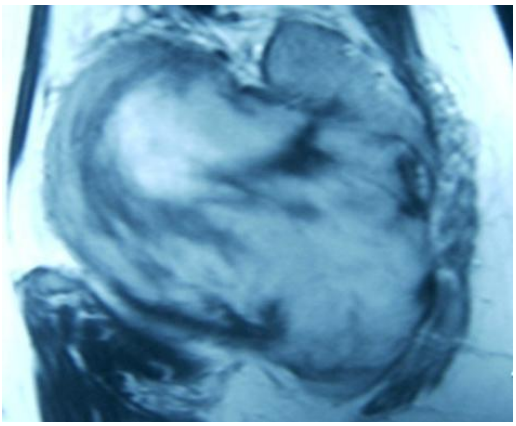

Figure 3: The mass is exposed and dissected from the pelvic structures

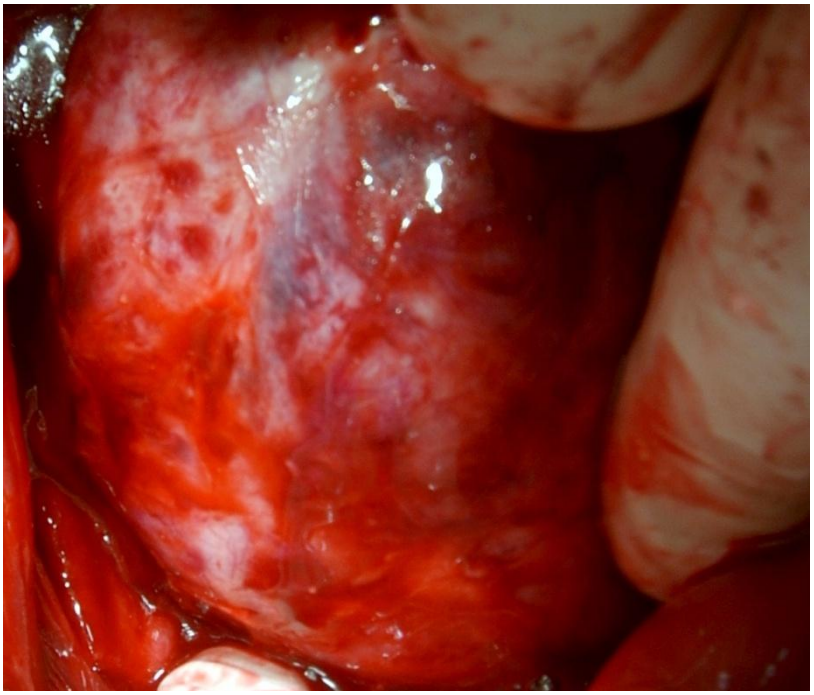

Figure 4: The tumor cells are CD56 positive (x200)