

Gastrointestinal Stromal tumor of the stomach and retroperitoneal paraganglioma in Saudi woman, “A case report”

Dalal Nemenqani.

Department of Pathology ,College Of Medicine, Taif University , Taif, Kingdom of Saudi Arabia.

Abstract

Gastrointestinal stromal tumor (GIST) and paraganglioma are uncommon tumors; mostly occur in a sporadic and isolated form. They are occasionally components of 3 clinical syndromes, familial paraganglioma and gastric GIST, neurofibromatosis type 1 and Carney triad. The latter does not show genetic mutations and affects young women predominantly. This article reports the occurrence of GIST and retroperitoneal paraganglioma in young Saudi woman aged 22 years. The initial clinical presentation was acute severe gastric bleeding. Gastric mass with retroperitoneal mass was discovered during surgical exploration. Histological and immunohistochemical study of both masses showed features of GIST and paraganglioma. The combination of GIST and retroperitoneal paraganglioma in the reported case may be incomplete expression of Carney triad or be coincidental occurrence.

Key words: Gastric GIST, Retroperitoneal paraganglioma, Carney triad, immunohistochemistry

Introduction:

Gastrointestinal stromal tumor (GIST) and paraganglioma are uncommon tumors mostly occur in a sporadic and isolated form. They occasionally arise in the setting of 3 clinical syndromes, familial paraganglioma and GIST (1), neurofibromatosis, type I (2) and Carney triad (3). Carney triad is a rare condition with fewer than 100 cases reported in the literature worldwide. In most cases, there is incomplete expression of the triad with only 2 of the 3 neoplasms seen at first presentation (4, 5&6).

Clinical Presentation:

A 22-year old female presented to hospital with acute severe gastric bleeding. Surgical exploration revealed big gastric mass in the posterior wall of body and antrum and another retroperitoneal mass. Surgical resection of both masses was done.

Pathological Features:

Gross examination of the gastric mass revealed intramural mass. The mass was partially covered by mucosa, measuring

9.5 x 6.5 x 5.0 cm with grayish cut surface. The retroperitoneal mass appeared oval in shape, capsulated, well-defined with 6.5 x 5.5 x 5.0 cm dimensions and grayish white solid cut surface.

Histopathological examination and immunohistochemical analysis were performed in tissue fixed in 10% formalin and embedded in paraffin. Immunohistochemical studies were done using CD 117 monoclonal antibody (1:20, Novocastra), CD 117 polyclonal antibody (1:300 DAKO), NSE monoclonal antibody (1:400, DAKO), Synaptophysin monoclonal antibody (1:40, DAKO), Chromogranin monoclonal antibody (1:200, DAKO), CD34 monoclonal antibody (1:100, DAKO), S100 polyclonal antibody (1:1000, DAKO), SMA monoclonal antibody (1:400 DAKO) and BCL2 monoclonal antibody (1:50, DAKO). Novocastra Streptavidin- HRP was used as detection system and DAB as the chromogen.

Sections from gastric mass revealed intramural neoplasm composed of bland appearing spindle cells arranged in bundles and short fascicle with focal nuclear palisading(Fig. 1A & B). The cells showed elongated nuclei and pale stained cytoplasm. The lesion was multifocal separated by bundles of residual muscularis propria. Areas of epithelioid cell morphology were noted. (Fig.1C). Mitotic count was 5/50 HPF. No evidence of necrosis could be seen. Immunohistochemistry: Polyclonal CD 117 (DAKO) and CD 34 showed diffuse strongly immunopositivity (Fig2A& B).

BCL 2 was weakly positive. Monoclonal CD 117 (Novocastra), SMA, Desmin and S100 were negative.

Sections from retroperitoneal mass disclosed capsulated neoplasm composed of small polygonal cells with round nuclei and eosinophilic cytoplasm arranged in nests and surrounded by vascular fibrous septa(Fig.3A). Immunohistochemistry: NSE, Synaptophysin and Chromogranin showed strongly immunoreactivity. S100 was positive (subtentacular network) (Fig3 B, C&D). Polyclonal CD 117 (DAKO) was negative.

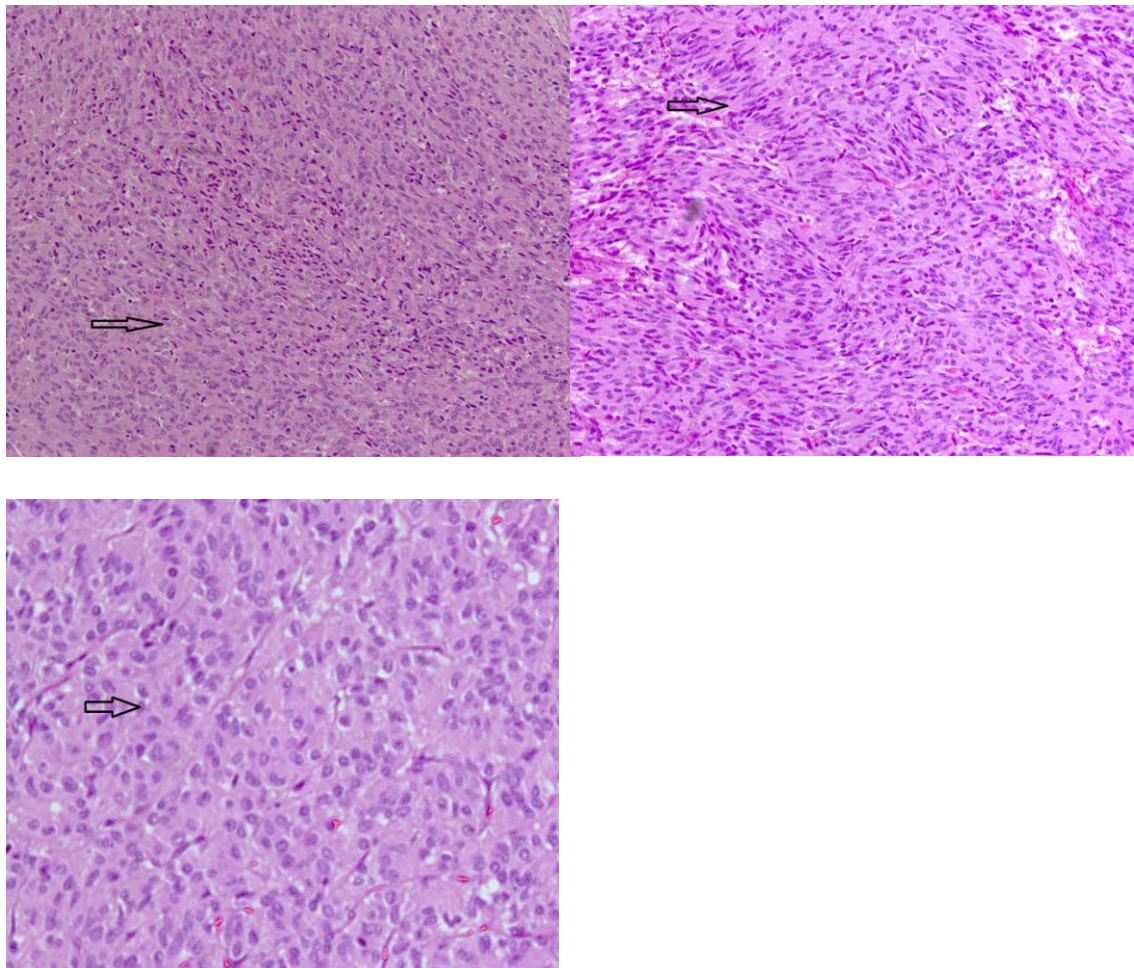


Fig1a : GIST showing spindle cell areas (H&E x 200).

Fig 1b : GIST showing spindle cell areas with with focal nuclear pallisading areas (H&E 200).

Fig1c : GIST showing epithelioid cell areas (H&E x 400).

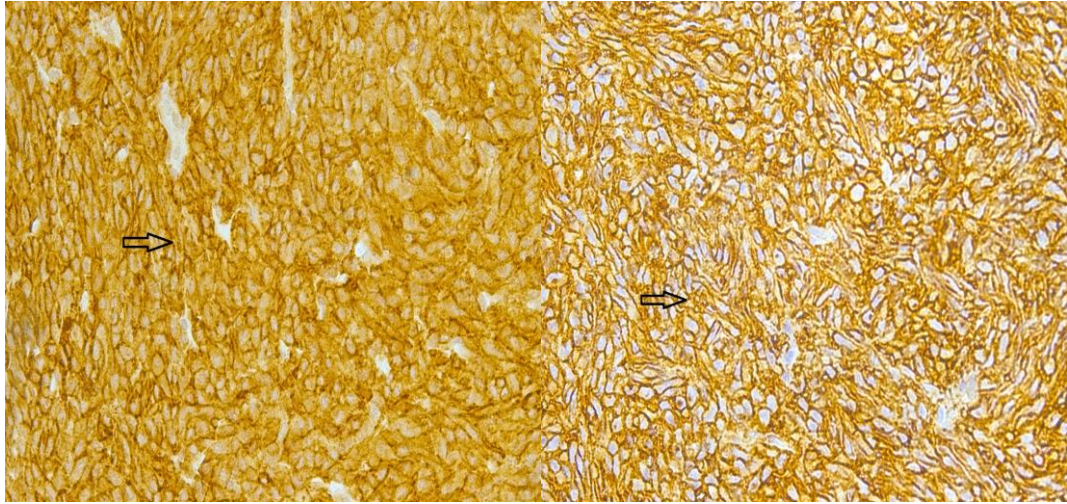


Fig2a :Immunohistochemical findings in GIST with strong diffuse CD117 immunoreactivity. (Streptavidin- Biotin technique x 400)

Fig2b :Immunohistochemical findings in GIST with Strong membranous CD34 immunopositivity (Streptavidin- Biotin technique x 400)

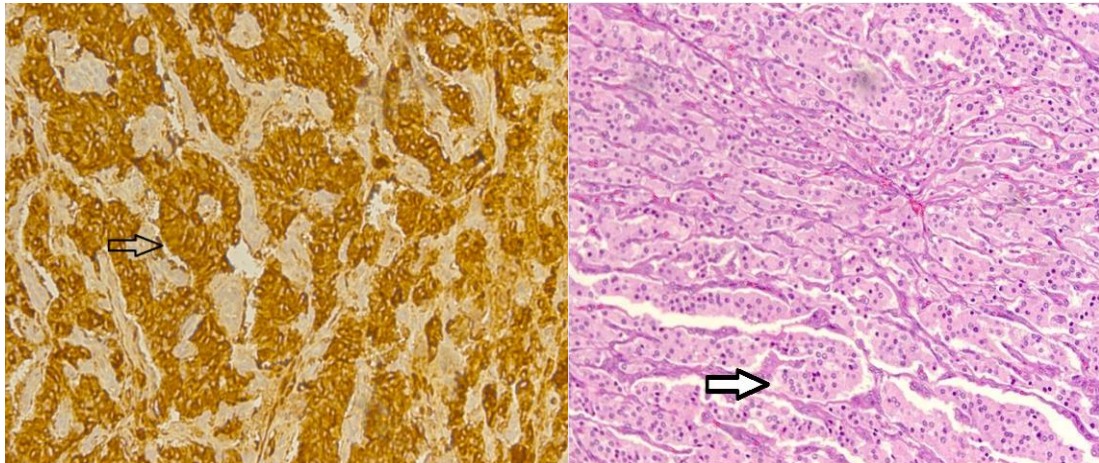


Fig3a : Paraganglioma showing nests of round cells separated by fibrous septa (H&E x 100).

Fig3b: Paraganglioma showing strong diffuse immunopositivity of Chromogranin (Streptavidin- Biotin technique x 400).

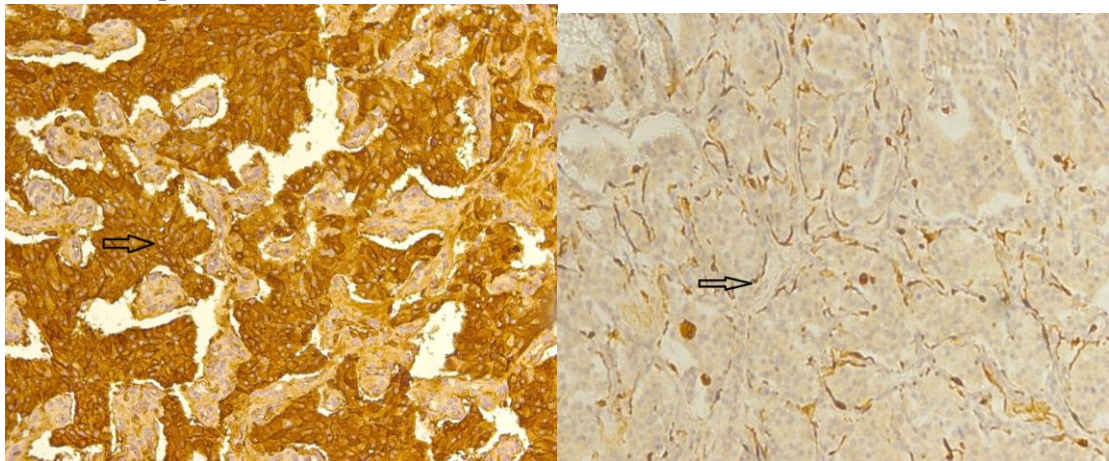


Fig3c : Paraganglioma showing strong diffuse immunoreactivity of Synaptophysin (Streptavidin- Biotin technique x 400).

Fig3d :Paraganglioma showing S100 positivity in subtentacular pattern.(Streptavidin- Biotin technique x 200).

Discussion:

Carney triad related GISTs have distinctive clinicopathologic features that differ from sporadic GISTs. These features are striking female predominance (85% of cases), young age at presentation (most patients less than 30 years of age), frequent gastric location (antrum and body) and relatively indolent clinical course despite high rate of local recurrence and metastases(3,4&5). GIST associated with Carney triad lack KIT and PDGFA mutations unlike sporadic GISTs that are known to have either KIT or PDGFA (6&7) Histologically, the vast majority of cases exhibit epithelioid and mixed spindle and epithelioid cell morphology(3,4&8). Multifocal gastric GISTs are frequently seen in Carney triad and in pediatric GISTs (9). It is generally accepted that the most important prognostic factors are size with threshold levels of 2.0 cm, 5.0 cm and 10 cm and mitotic index of 5 mitoses per 50/hpf.

However, small GISTs with a low mitotic index are known to metastasize (10, 11&12). Immunohistochemically, all cases stain for KIT (CD 117) with variable reactivity to CD 34 and BCL 2. A minority showed positive staining for SMA and S100 protein. No one of the cases express Desmin. CD 117 positivity is unusually diffuse and strong with cytoplasmic staining and membrane accentuation (8, 11, 12 & 13). Some investigators stated that best ones are available for formalin-fixed and paraffin embedded tissue are polyclonal antibodies. The monoclonal antibodies available react inconsistently in formalin fixed and paraffin embedded tissue and identifies only a minority of GISTs (13 & 14). The present case showed monoclonal Novocastra CD 117 negative immunoreactivity in contrast to strong diffuse positivity when sections stained by polyclonal CD 117 (DAKO).Dual expression of CD 117 in

both GIST and paraganglioma was described in one report (15). Ultrastructurally, some GIST showed well-developed cell processes, neurosecretory granules, rudimentary cell junctions and microtubules. These features were characteristic for diagnosis of gastrointestinal autonomic nervous tumors (GANT) . Some of these GANTs were observed in patients with Carney triad. Some authors considered that GANTs should be regarded as a type of GIST because of their identical c-KIT mutation and CD117 immunopositivity (16&17). The main differential diagnosis of GIST included smooth muscle tumors, schwannoma, inflammatory fibroid polyp and desmoid tumor. Immunohistochemical analysis is very useful in the differential diagnosis (9, 12&13). The familial paraganglioma- GIST syndrome differs from Carney triad by absence of female predilection, autosomal dominant inheritance pattern and predominance of paragangliomas (1).

Conclusion:

-The lack of germline mutations in Carney-related GIST suggests a different pathogenetic pathway.

-Based on the clinicopathologic features and immunohistochemical studies, the GIST-paraganglioma combination in the present case may represent either incomplete or partial Carney triad or be coincidental occurrence.

-Lifelong follow up is required to monitor local recurrence and metastases and to exclude the development of pulmonary chondroma.

References:

1. **Carney JA and Stratakis Ca (2002):** Familial paraganglioma and gastric stromal sarcoma: a new syndrome distinct from Carney triad *Am.J.Med.Geret* ; 108: 132-139.
2. **Takazawa YS, Sakurai S, Sakuma Y, et al (2005) :** Gastrointestinal stromal tumors of neurofibromatosis type I *Am.J.surg. Pathol*; 129: 755-763
3. **Carney AJ, Sheps SG, Go VI, et al (1977):** The triad of gastric leiomyosarcoma, functioning extra-adrenal paraganglioma and pulmonary chondroma *N. Engl. J. Med*; 296: 1517-1518
4. **Carney AJ. (1999):**Gastric stromal sarcoma, pulmonary chondroma and extraadrenal paraganglioma (Carney triad): natural history, adrenocortical component and possible familial occurrence *Mayo.clin. Proc*, 74: 543-552
5. **Agaimy A, Plez A-F, Corless CL, et al (2007):** Epithelioid gastric stromal tumor of the antrum in young females with the Carney triad: A report of three new cases with mutational analysis and comparative genomic hybridization *Oncology reports*; 18: 9-15
6. **Miettinen M. Lasota J and sobin LH (2005):** Gastrointestinal stromal tumor of the stomach in children and young adults. A clinicopathologic, immunohistochemical and molecular genetic study of 44 cases with long term follow up and review of literature *Am J.surg.Path*; 29:1373-1381
7. **Dient J, Tamborini E, Casali P, et al (2005):** Carney triad: Case report and molecular analysis of gastric tumor *Hum.pathol*; 36: 112-116
8. **Miettinen M. Sobin LH and Lasota J. (2005):** Gastrointestinal stromal tumors of stomach: a clinicopathologic, immunohistochemical and molecular genetic study of 1765 cases with long term follow up *Am.j.surg. Pathol*; 29; 52-68
9. **Kirsh R, Goa Z-H and Riddell R. (2007):**Gastrointestinal stromal tumor: Diagnostic Challenges and practical approach to differential diagnosis *Adv. Anat. Path*; 14: 261-285
10. **DeMetteo RP, Lewis JJ, Leung D et al (2000):** Two hundred gastrointestinal stromal tumor, recurrence patterns and prognostic factors for survival, *Ann surg.* 231: 51-58
11. **Fletcher CD, Berman JJ, Corless et al (2002):** Diagnosis of gastrointestinal stroma tumor: a concensus approach *Hum. Pathol*; 33: 459-465
12. **Rubin BP.(2006):** Gastrointestinal stroma tumors: an update *Histopathology*; 48: 83-96
13. **Miettinen and lasota J. (2003):**Gastrointestinal stromal tumors (GISTs): Definition, occurrence, Pathology, Differential Diagnosis and molecular genetics *Pol J. path*; 543-24
14. **Badalamenti G, Rodolico V., Fulfaro F. et al (2007)** Gastrointestinal stromal tumors (GISTs): Focus on histopathological diagnosis and biomolecular features *Ann. Of oncol* ;18: 136-140
15. **Horenstein MG, Hitchcock TA and Toker JA (2005):**Dual CD 177 expression in gastrointestinal stromal tumor GIST and paraganglioma of Carney triad: a case report *Int.J.surg.Path* ; 13: 87-92
16. **Perez-Atayde AR, Shamberger RC, Kozakewich HW. (1993):**Neuroectodermal differentiation of gastrointestinal tumor in the Carney triad An ultrastructural and immunohistochemical study *Am.j.surg.pathology*; 17:706-714
17. **Lee JR, Joshi V, Griffin JW et al (2001):**Gastrointestinal autonomic nerve tumor: Immunohistochemical and molecular identity with gastrointestinal stromal tumor *Am.j.surg.pathology*; 25:979-987

تقرير لمتلازمة ورم لحيمي بالمعدة والمستقتمات خلف الصفاق

د. دلال محي الدين نمقاني

قسم علم الأمراض، كلية الطب، جامعة الطائف، الطائف، المملكة العربية السعودية

تعتبر أورام اللحمية المعوية من الأورام الغير شائعة و التي تحدث في الغالب في صفة متفرقة انفرادية ومعزولة. وقد تكون نادرا جزء من متلازمة مثل متلازمة الأورام المعوية اللحمية مع الأورام المستقتماتية والورم العصبي الليفي من النوع الأول و ثالوث كارني و التي لا تحتوي على أي طفرات جينية و تصيب السيدات الأصغر سنا.

نتقدم بوصف لمتلازمة في سيدة تبلغ 22 عام ومصابة بكتلتين خلف الصفاق والمعدة تم اكتشافهما وقت التشخيص.

حضرت المريضة للمستشفى بسبب نزيف حاد من المعدة و أوضحت الفحوصات و الاستكشاف الجراحي وجود ورم بالمعدة و خلف الصفاق . وأظهرت الدراسة النسيجية والمناعية وجود نوعين من الأورام معدي لحمي و مستقتماتي و الذي قد يكون جزء من متلازمة كارني أو توافق عشوائي.